

Giant Cell Tumour of Bone.

Benign or Malignant?

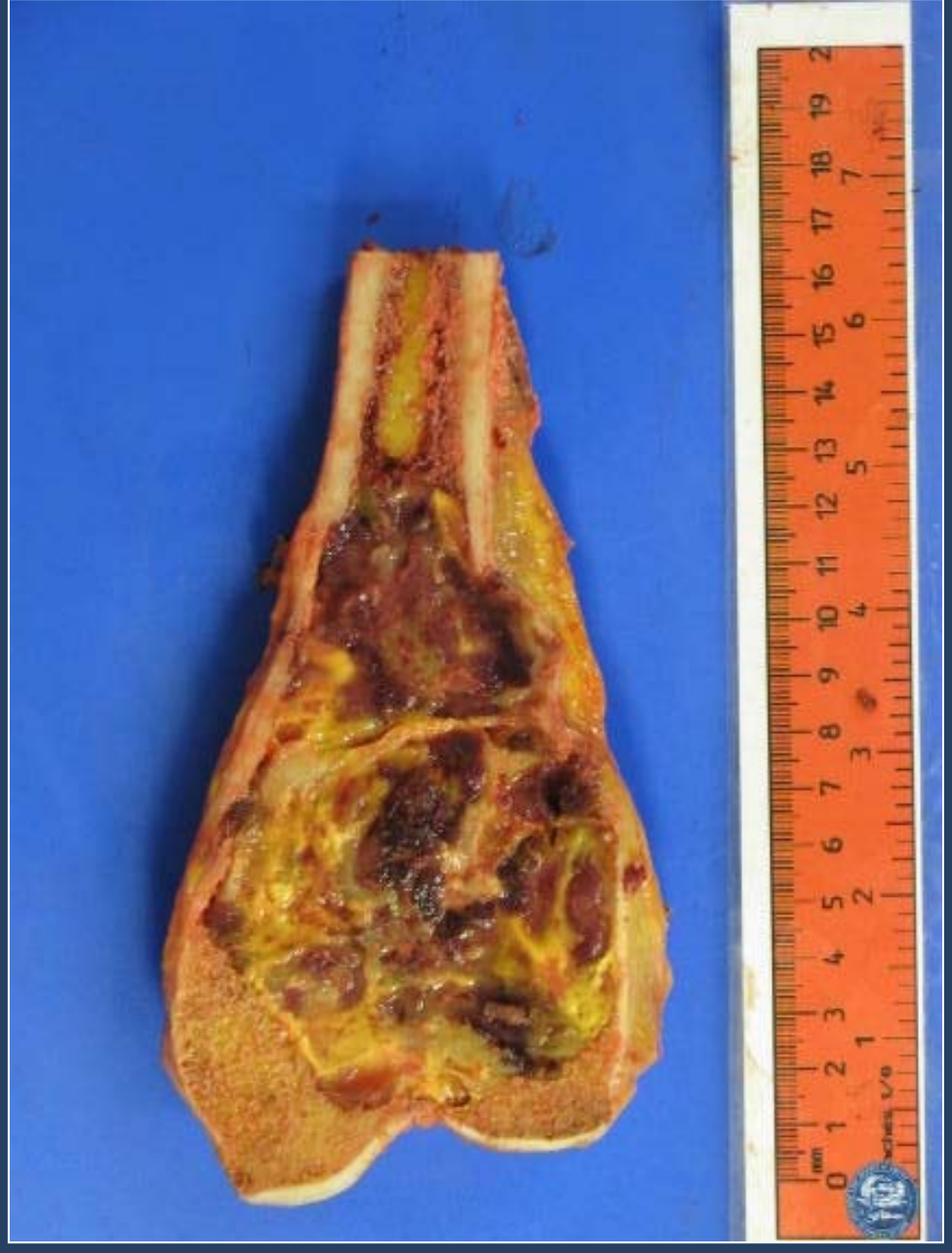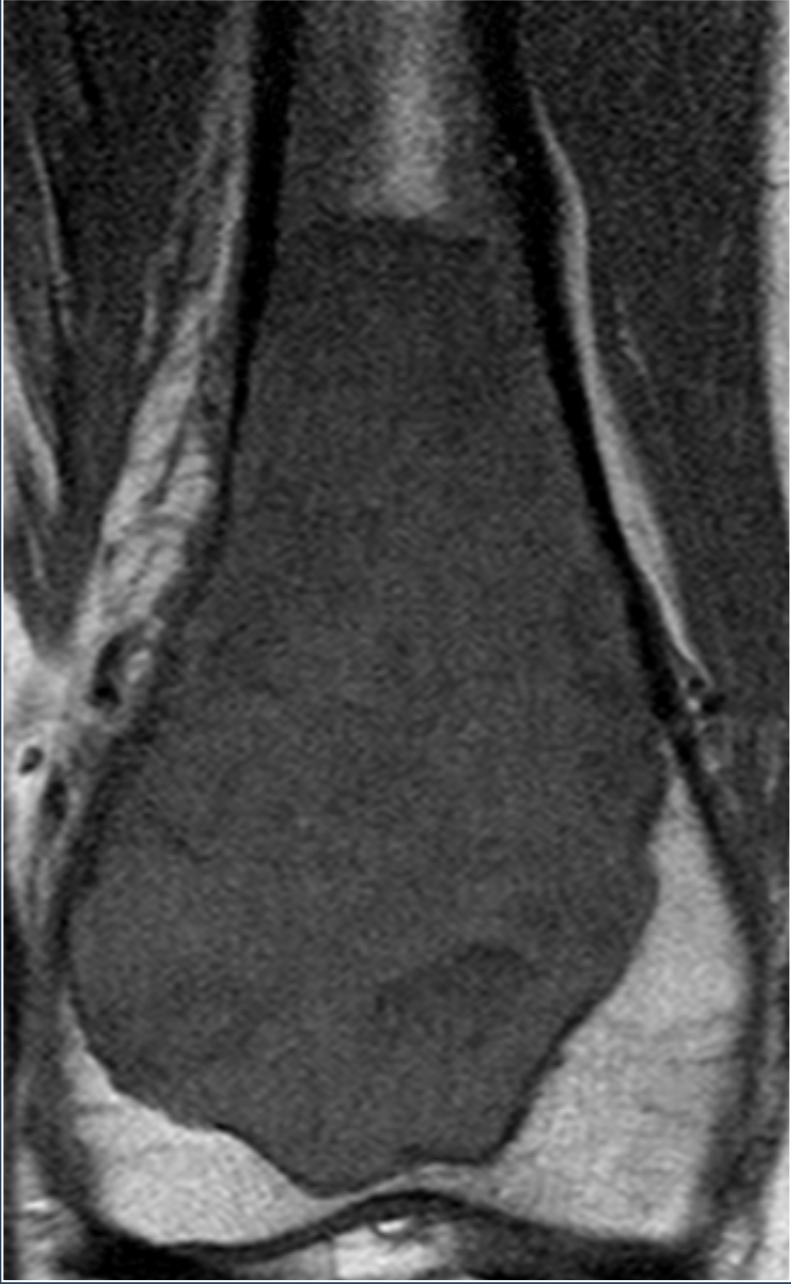I A P 2018

Roberto Tirabosco

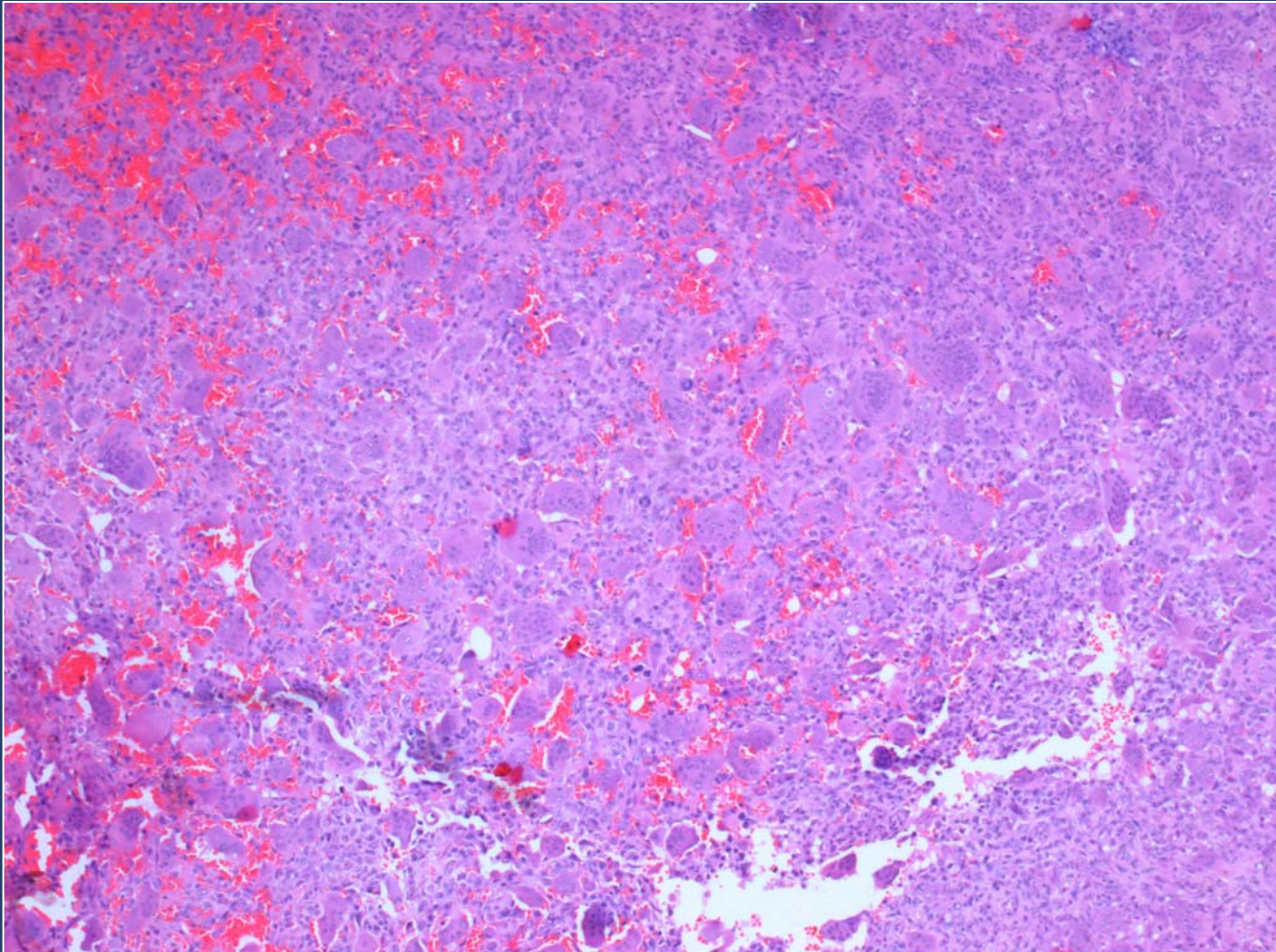


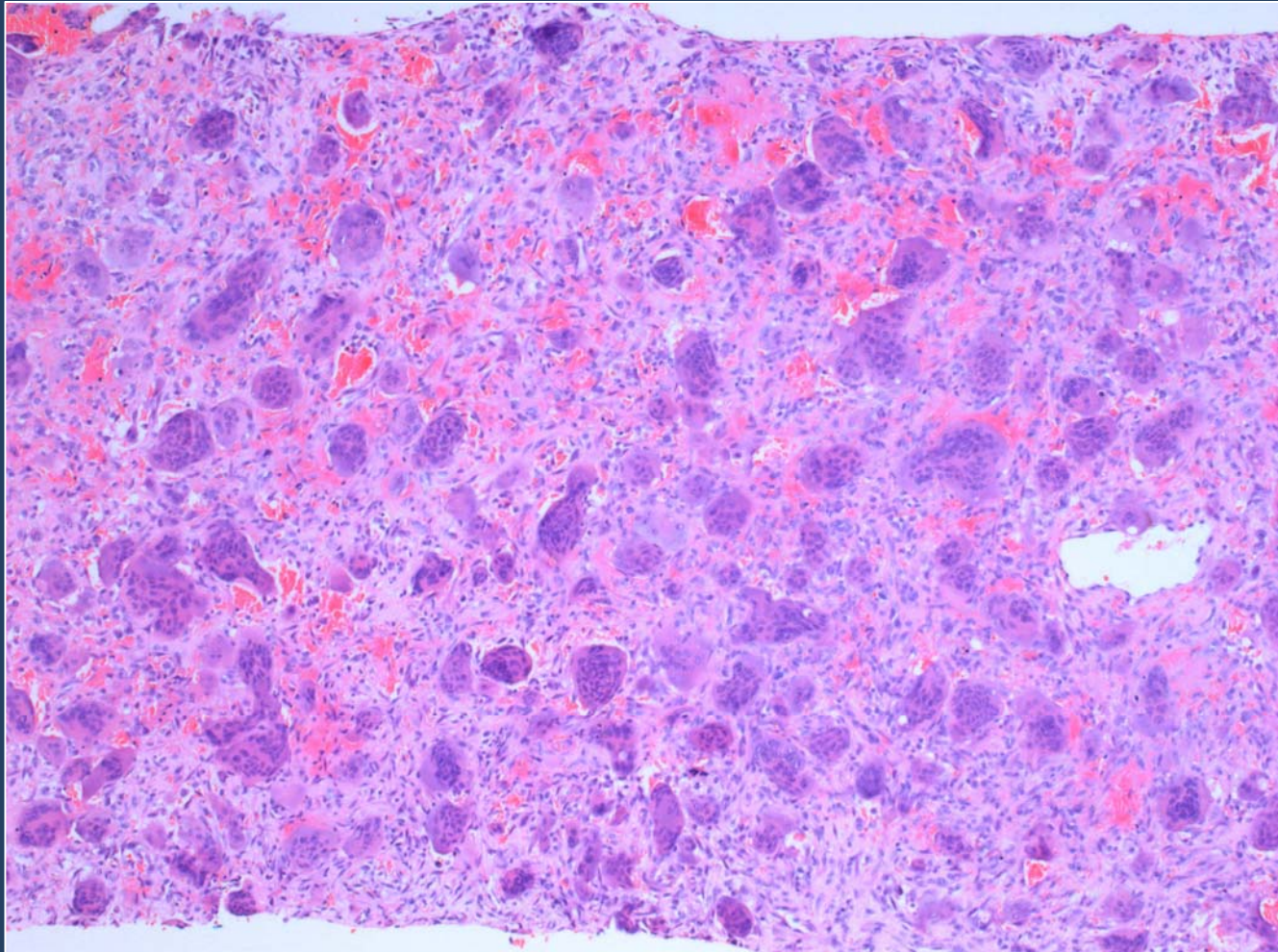
Giant Cell Tumour of Bone

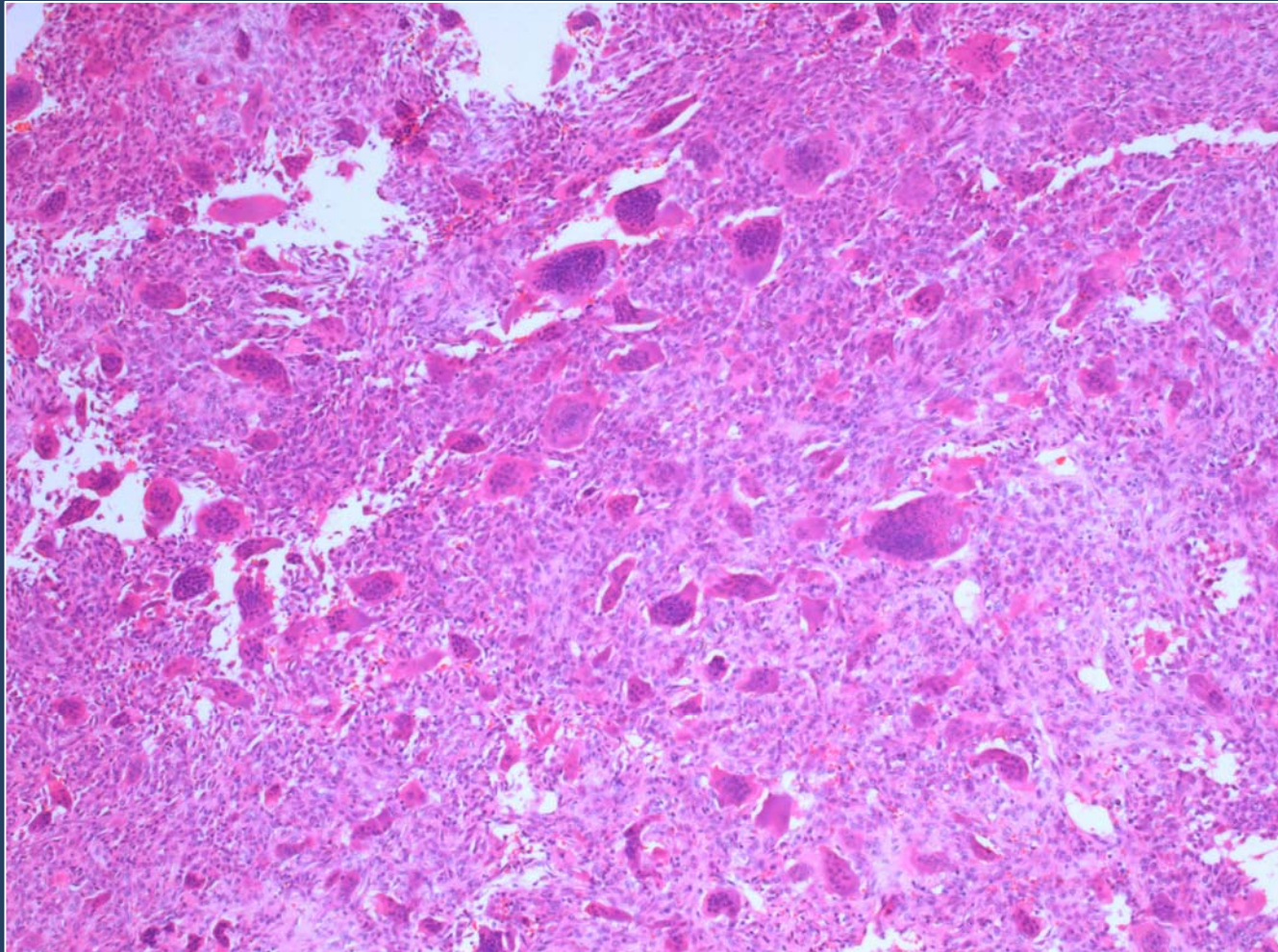
- Third decade. Rare in immature skeleton
- Epiphyseal tumour
- Any bone, mostly distal femur, proximal tibia and distal radius
- Vertebral sites most frequent in sacrum
- ~98% missense mutations in H3.3 gene (*H3F3A*) → G34W
- Locally aggressive, rarely metastasising
- Curettage or resection. Denosumab in surgically inoperable cases or recurrences

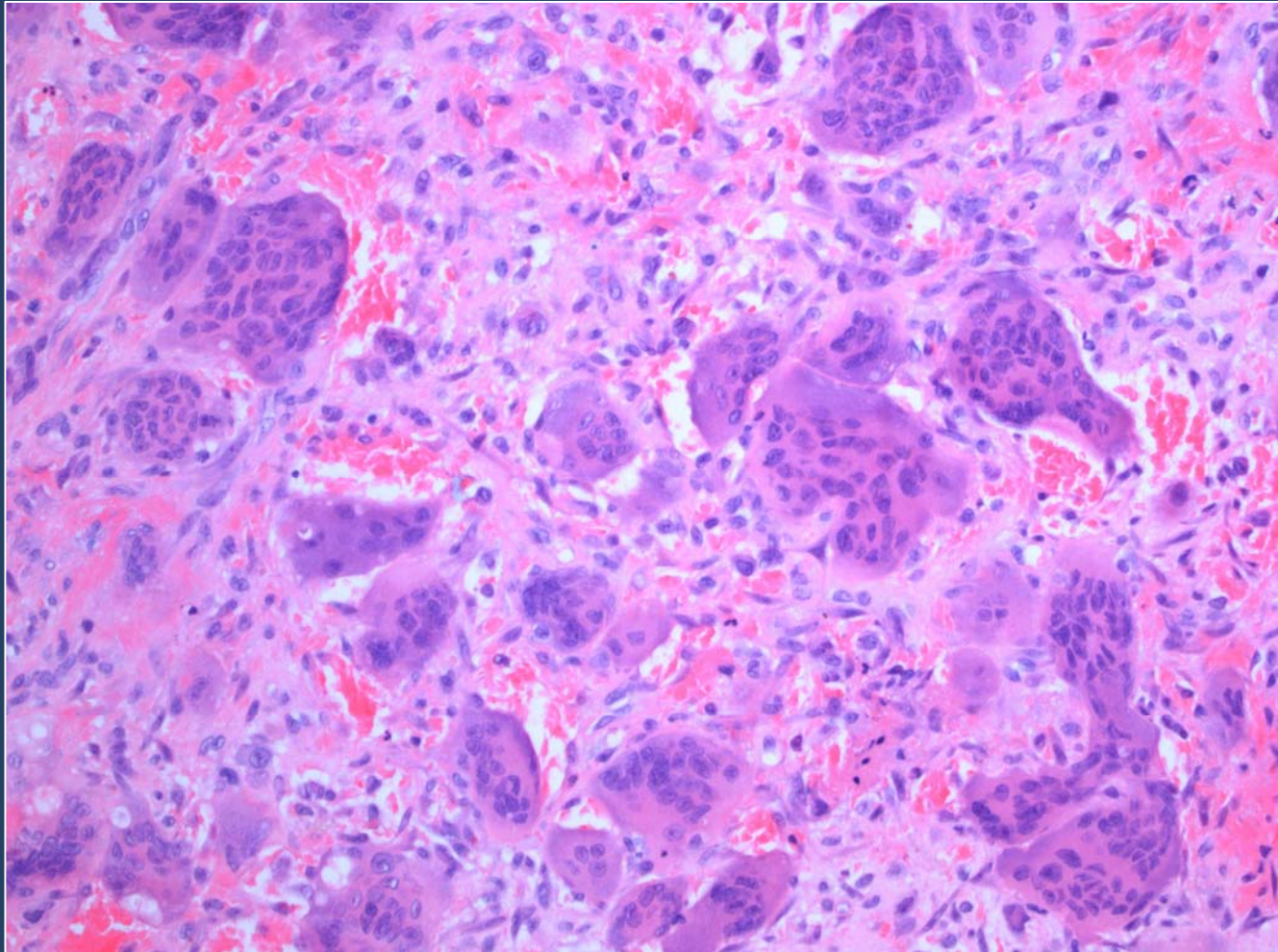


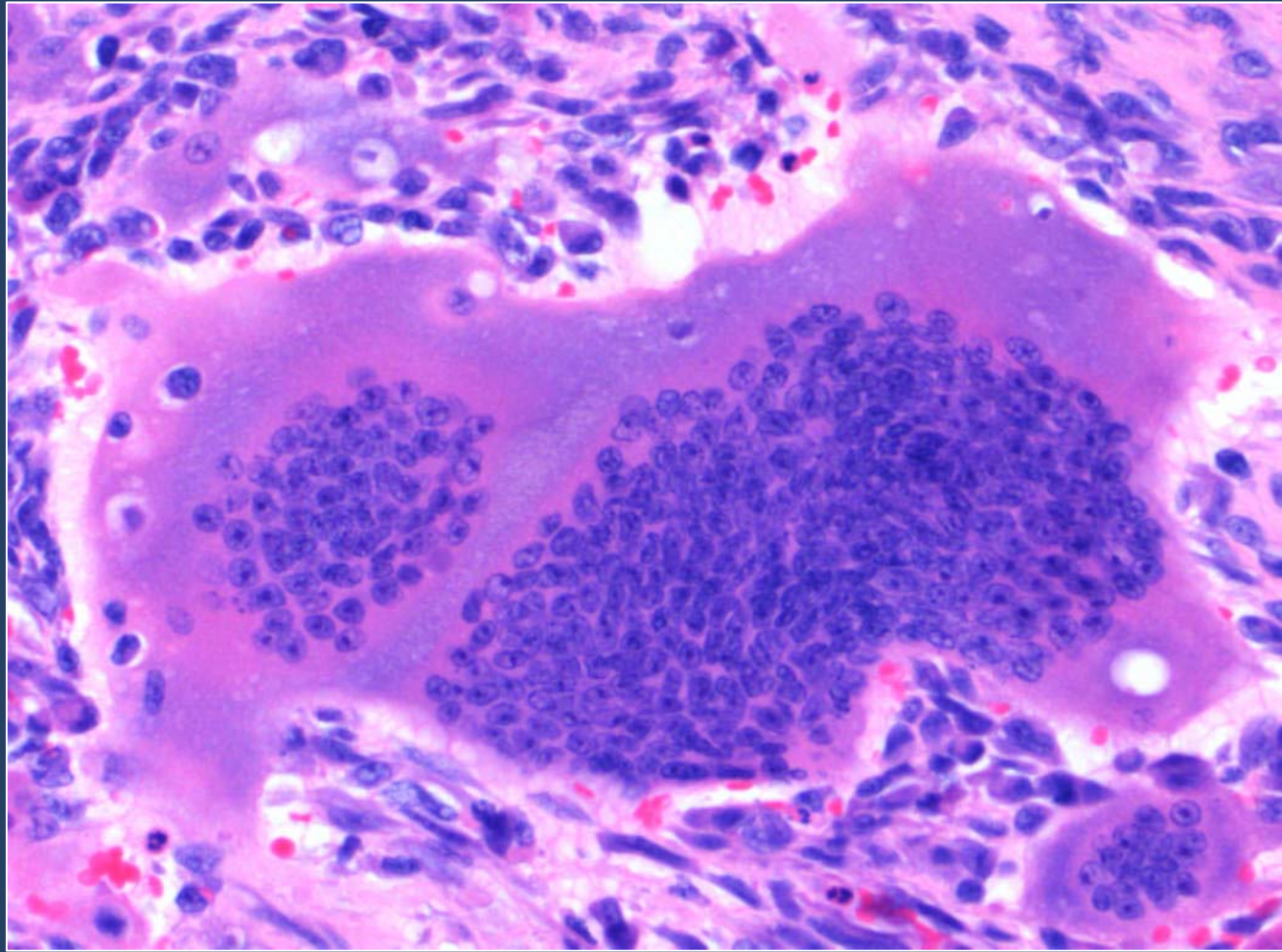
Classical appearance

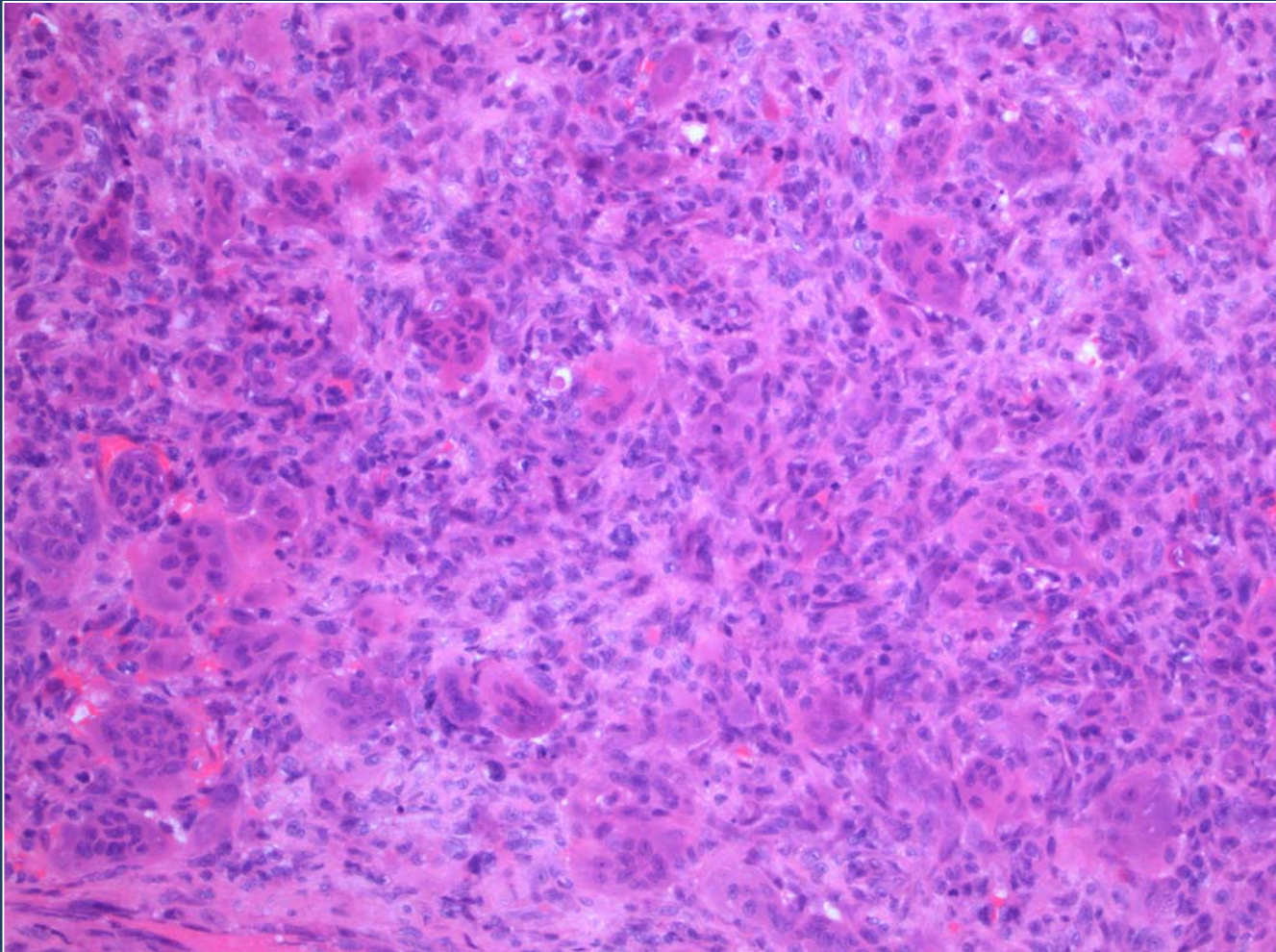


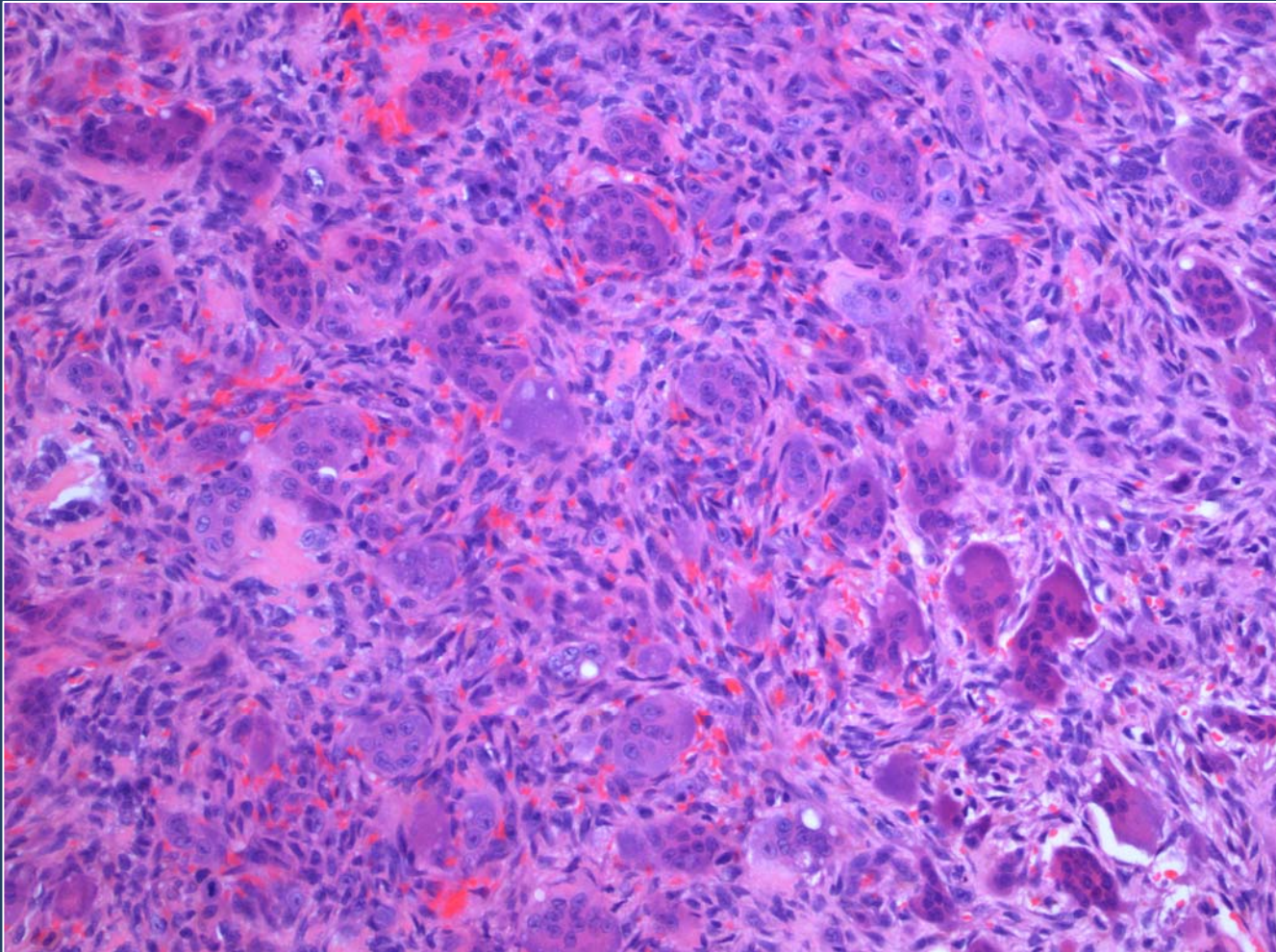


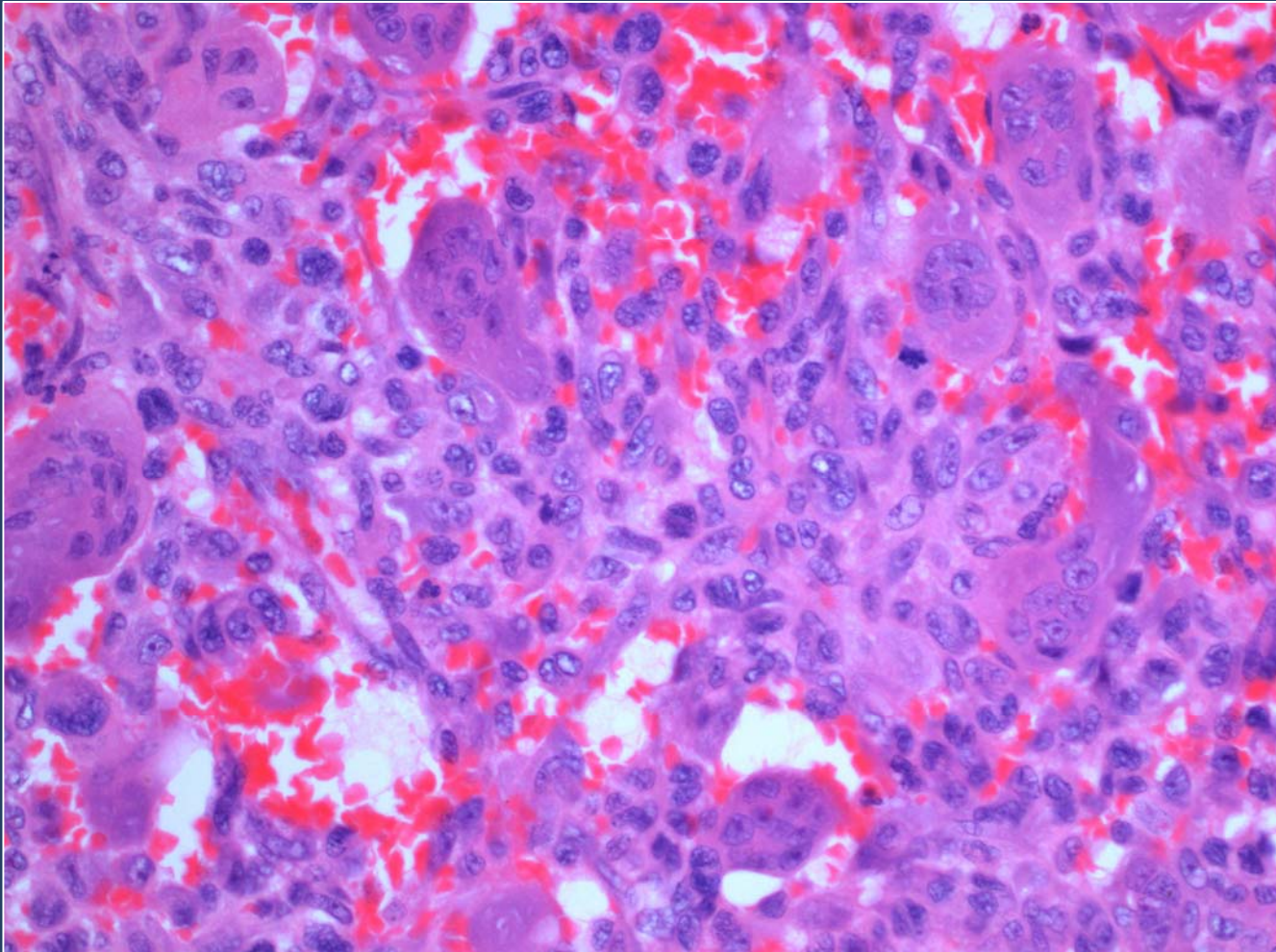




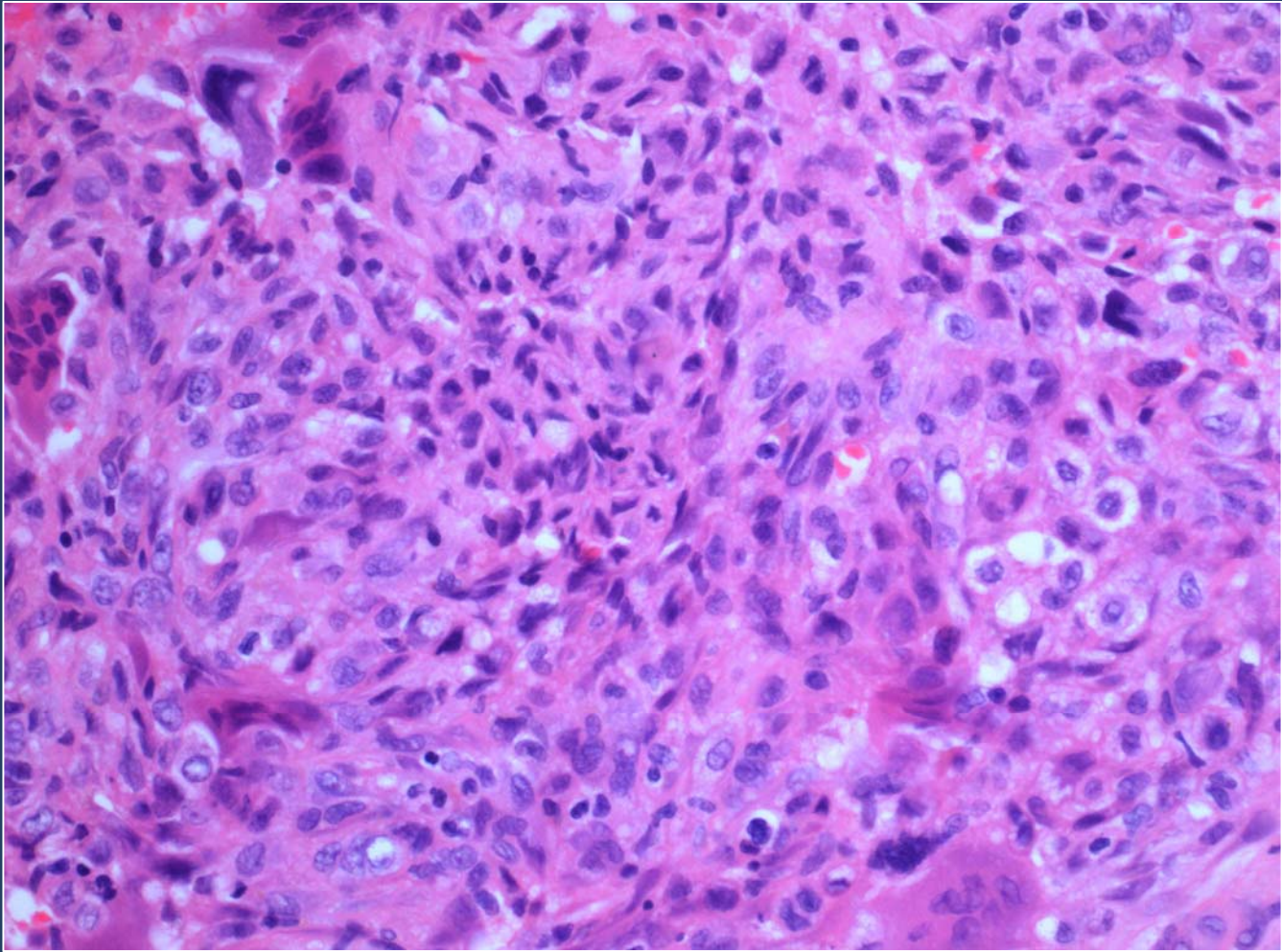


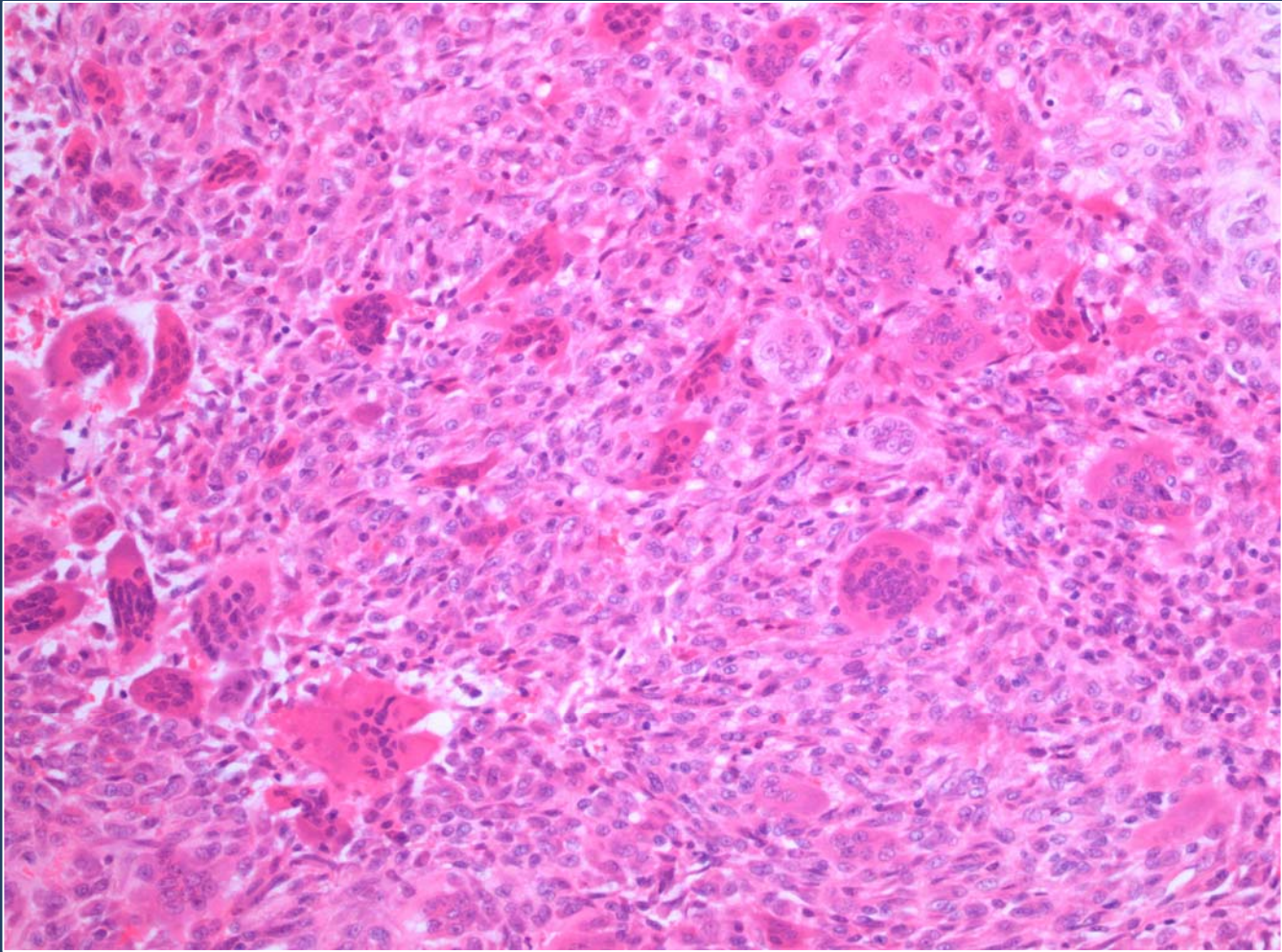


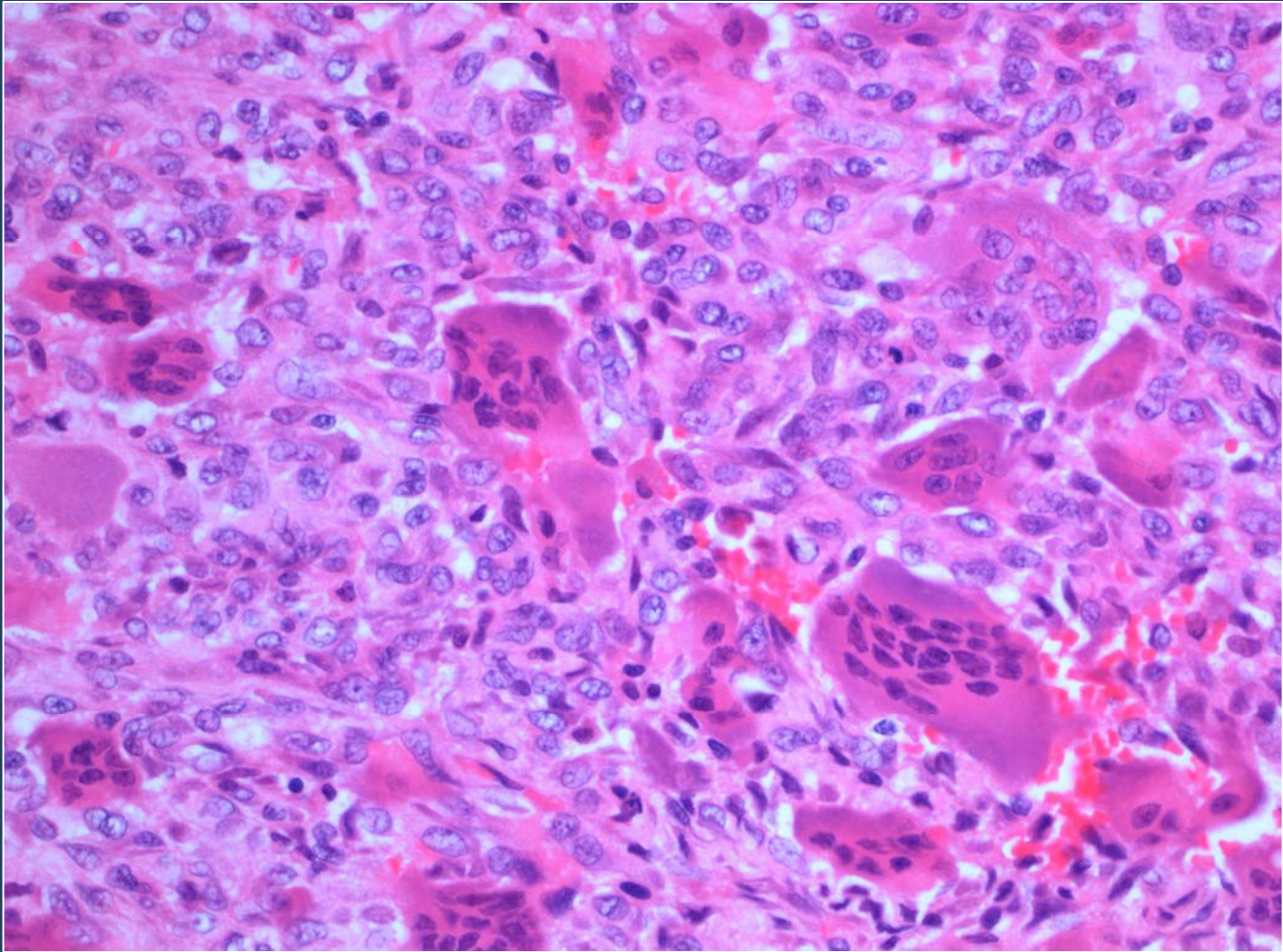




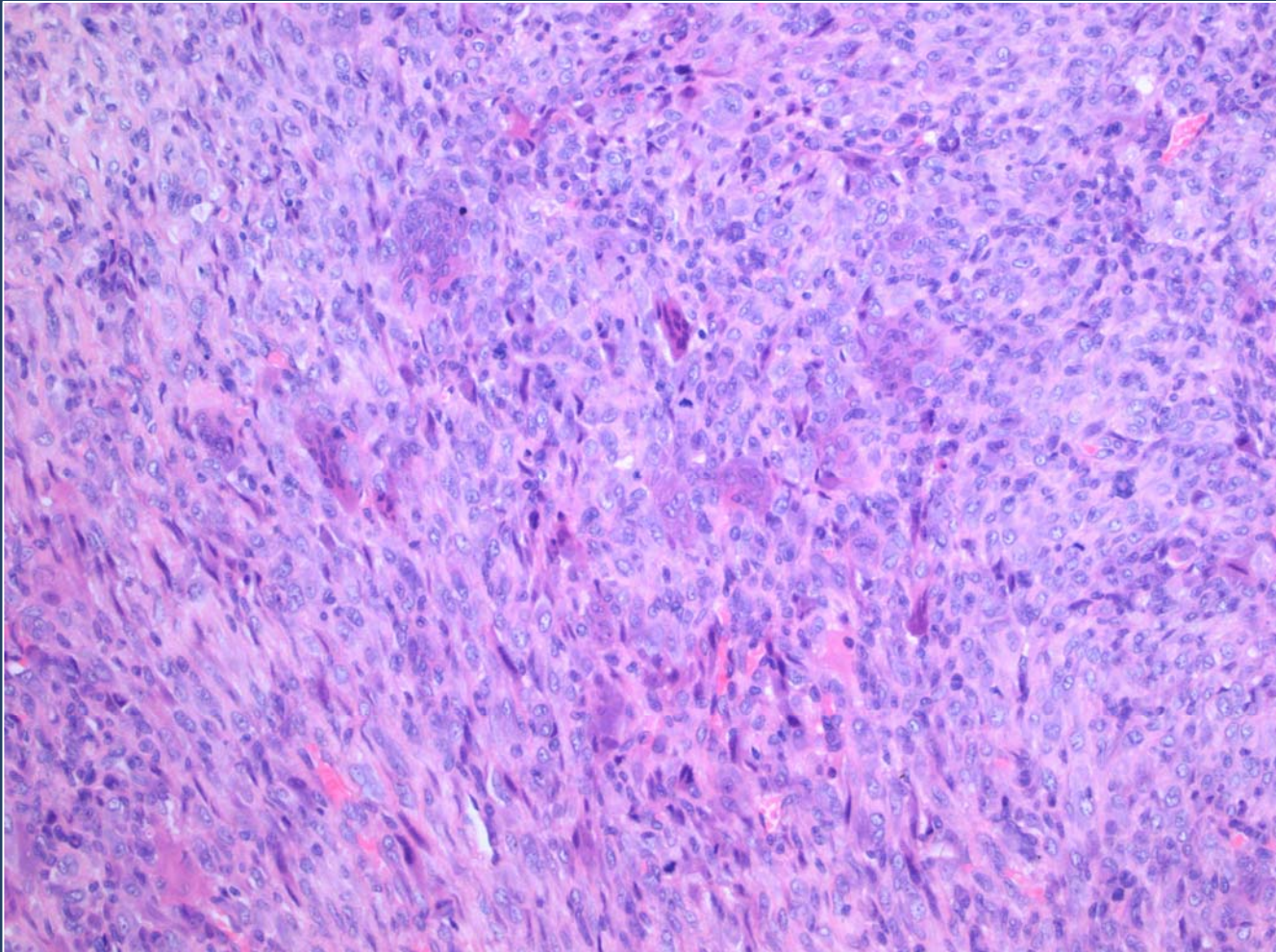
Mononuclear stromal cells ARE the neoplastic cells

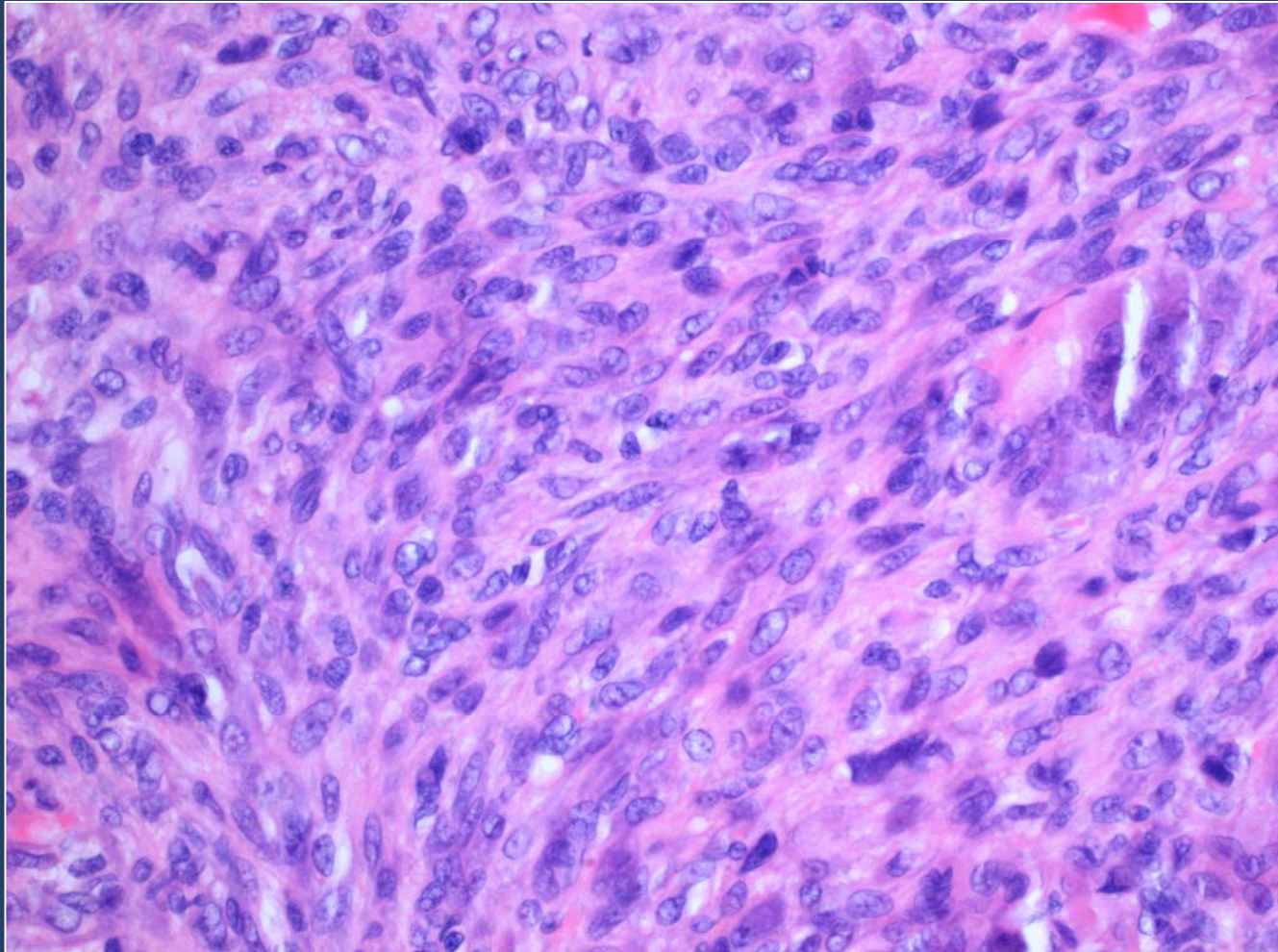


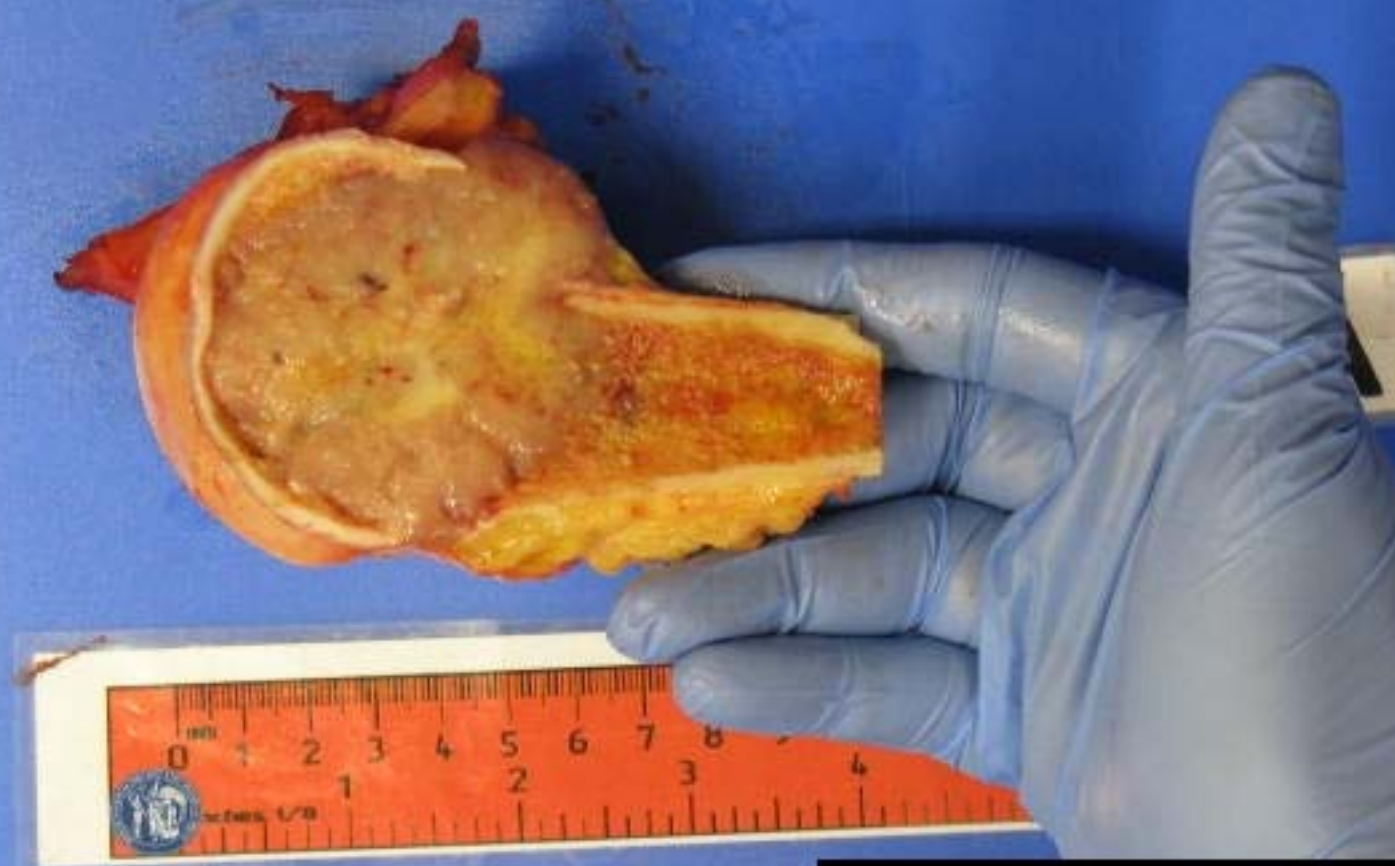




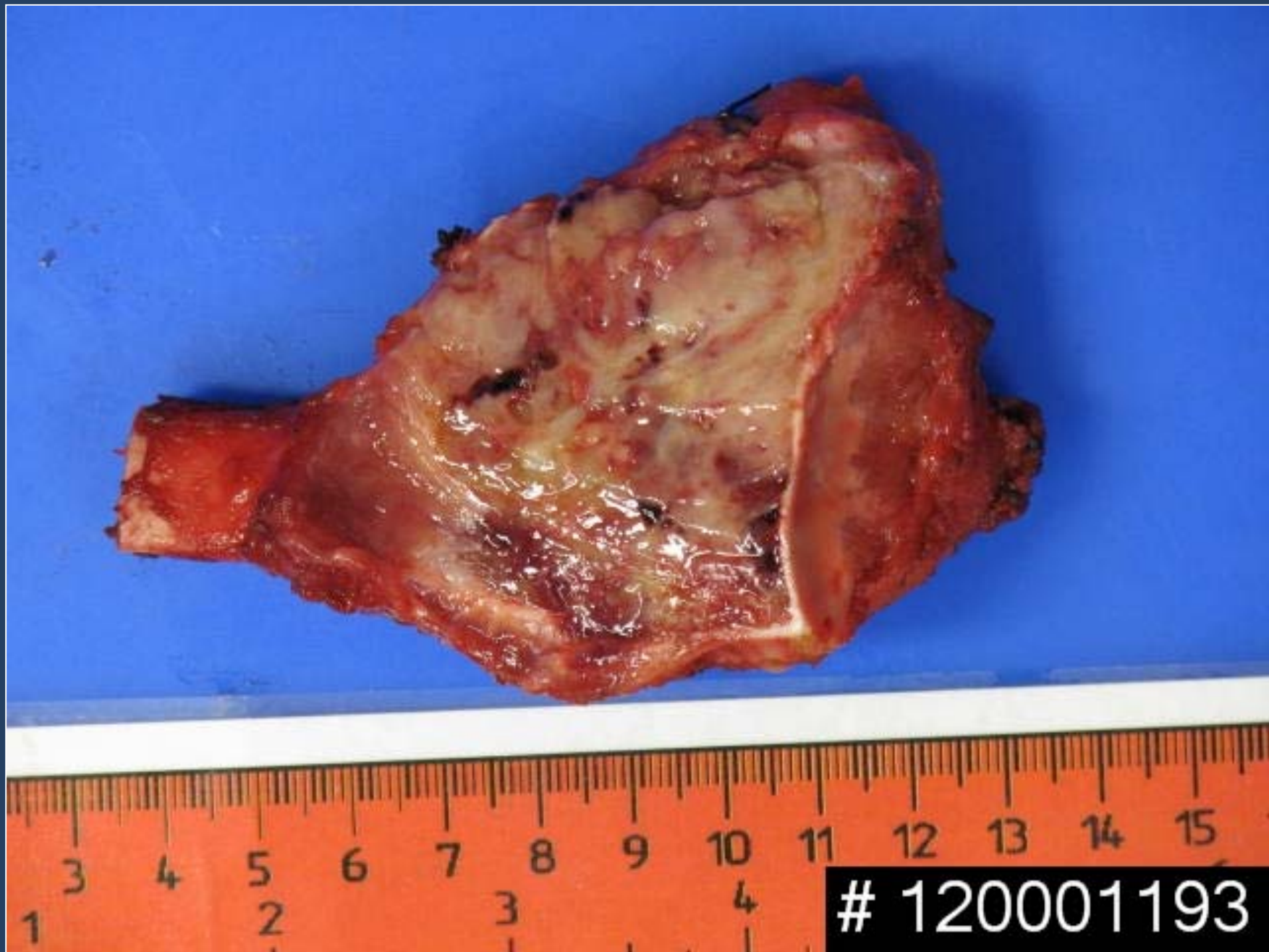Stromal overgrowth



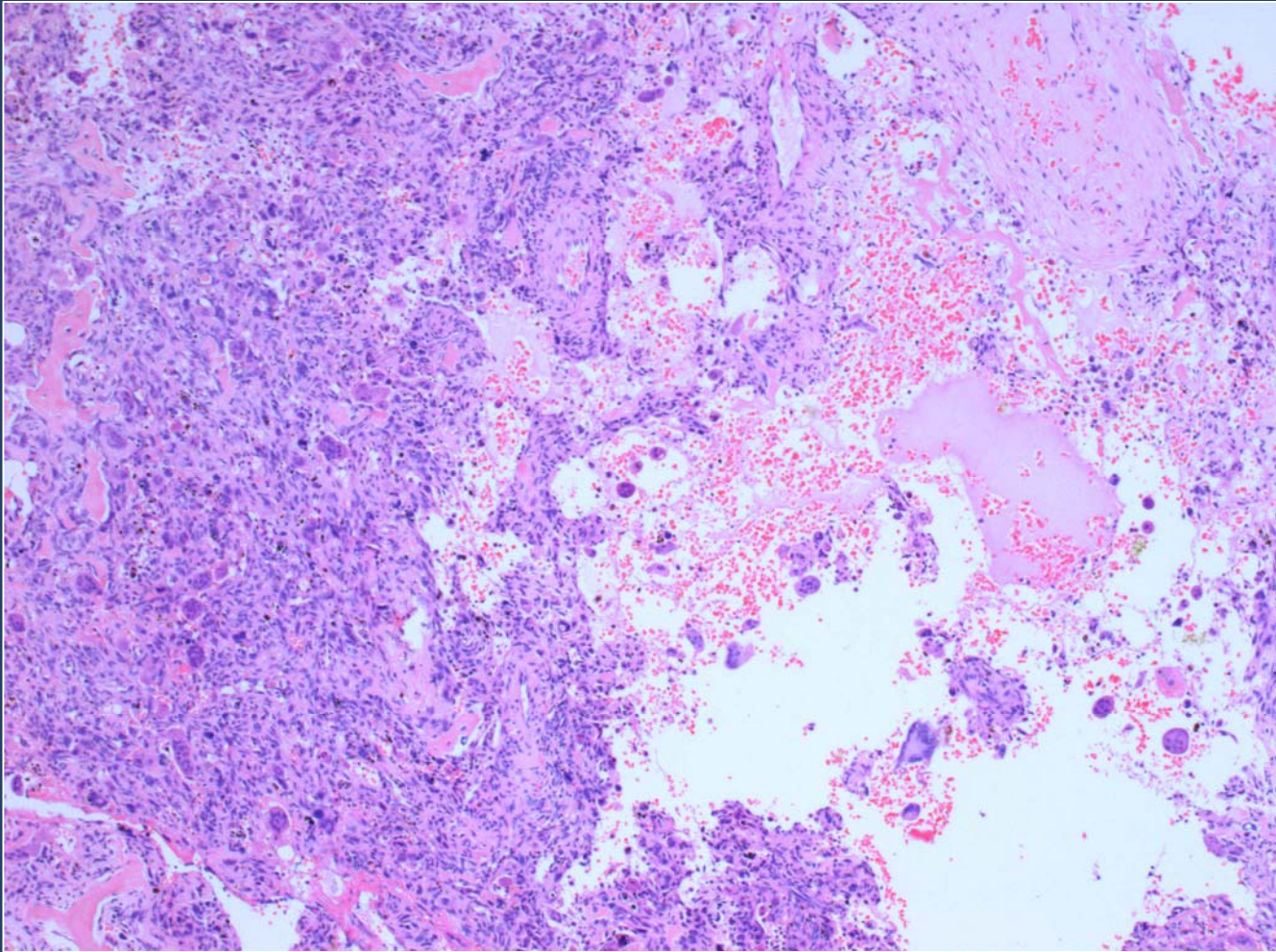




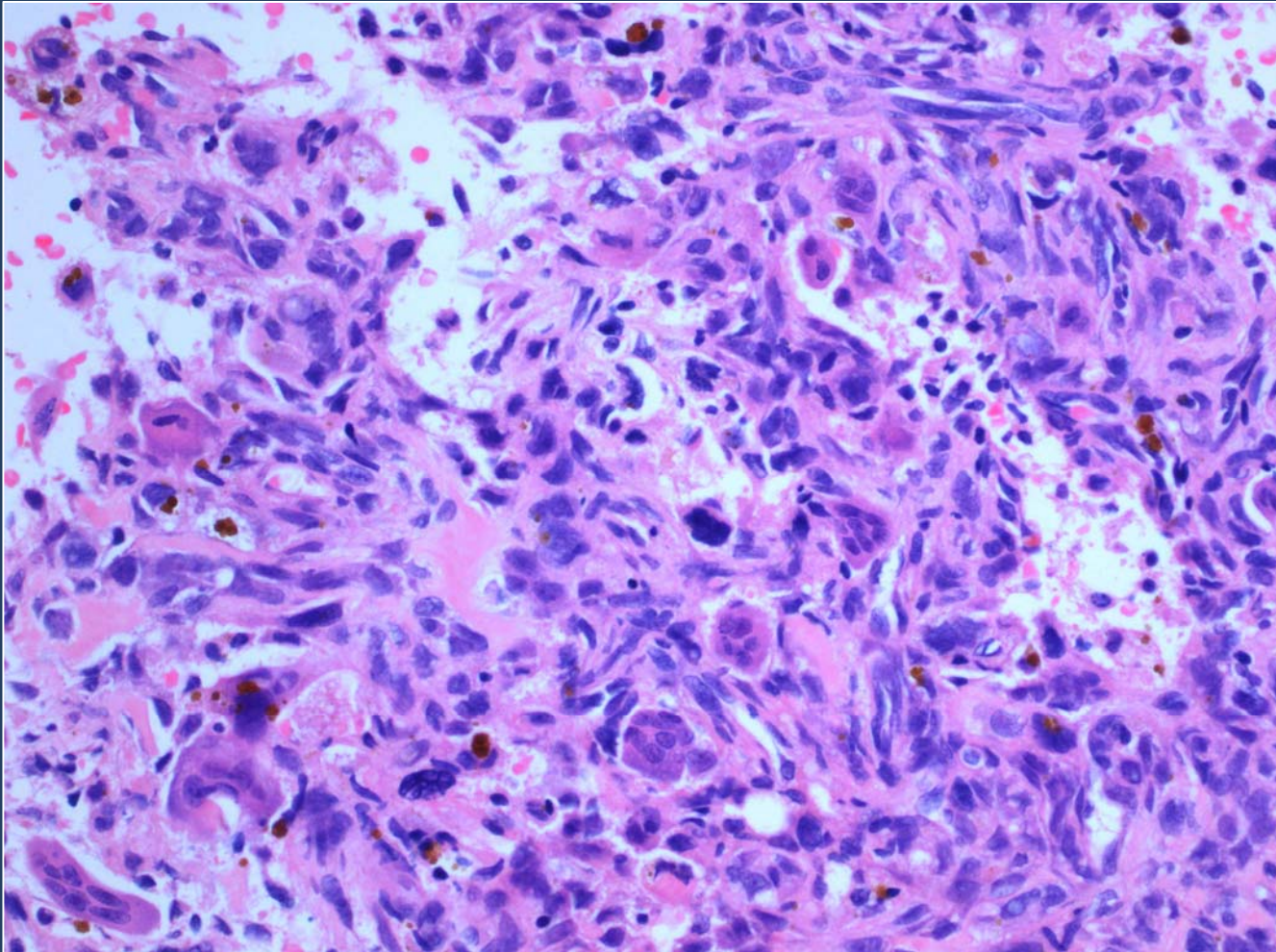
140000230

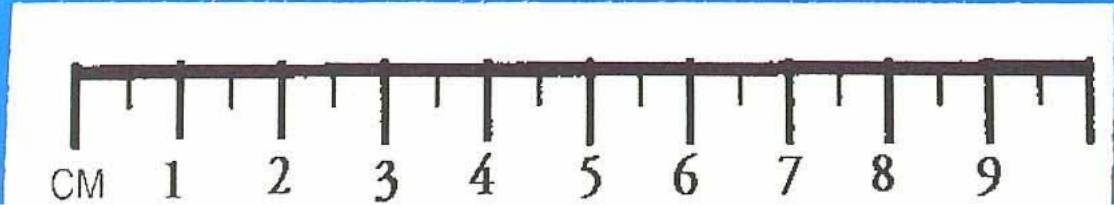
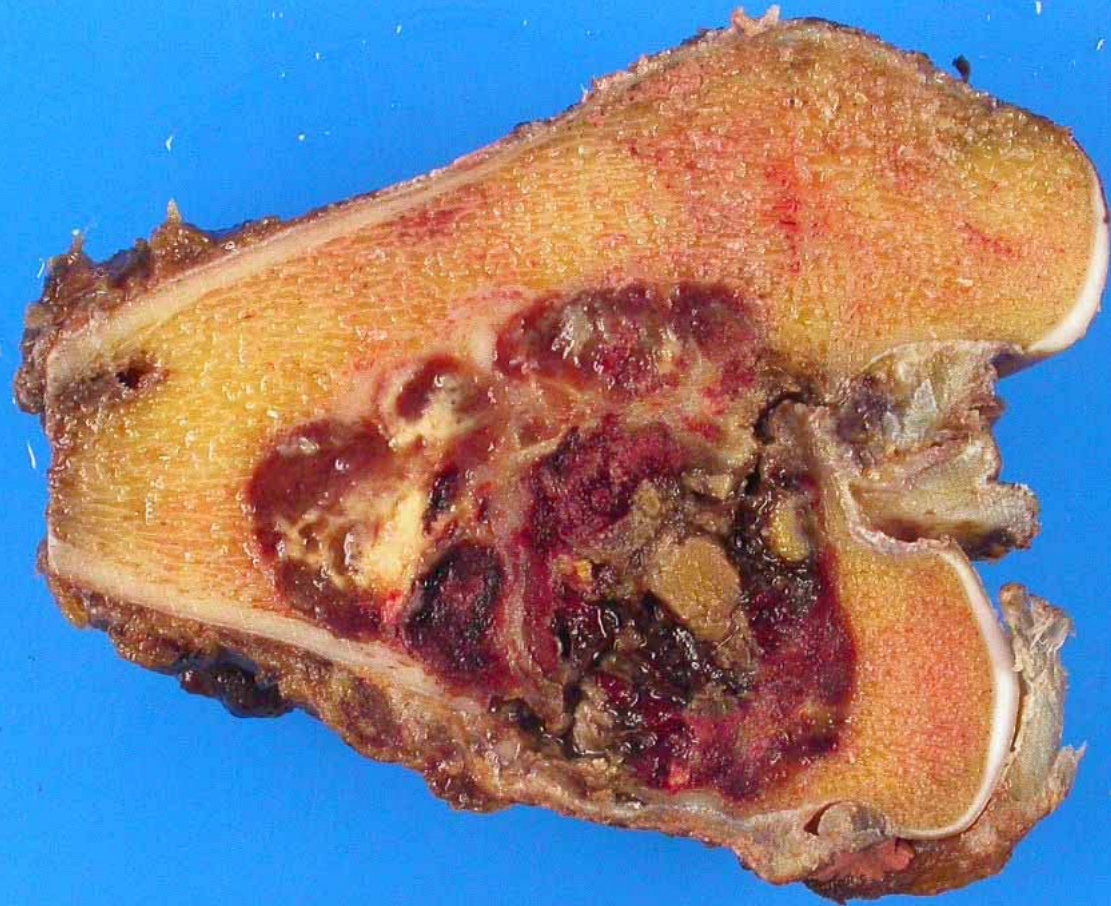
ABC-like change

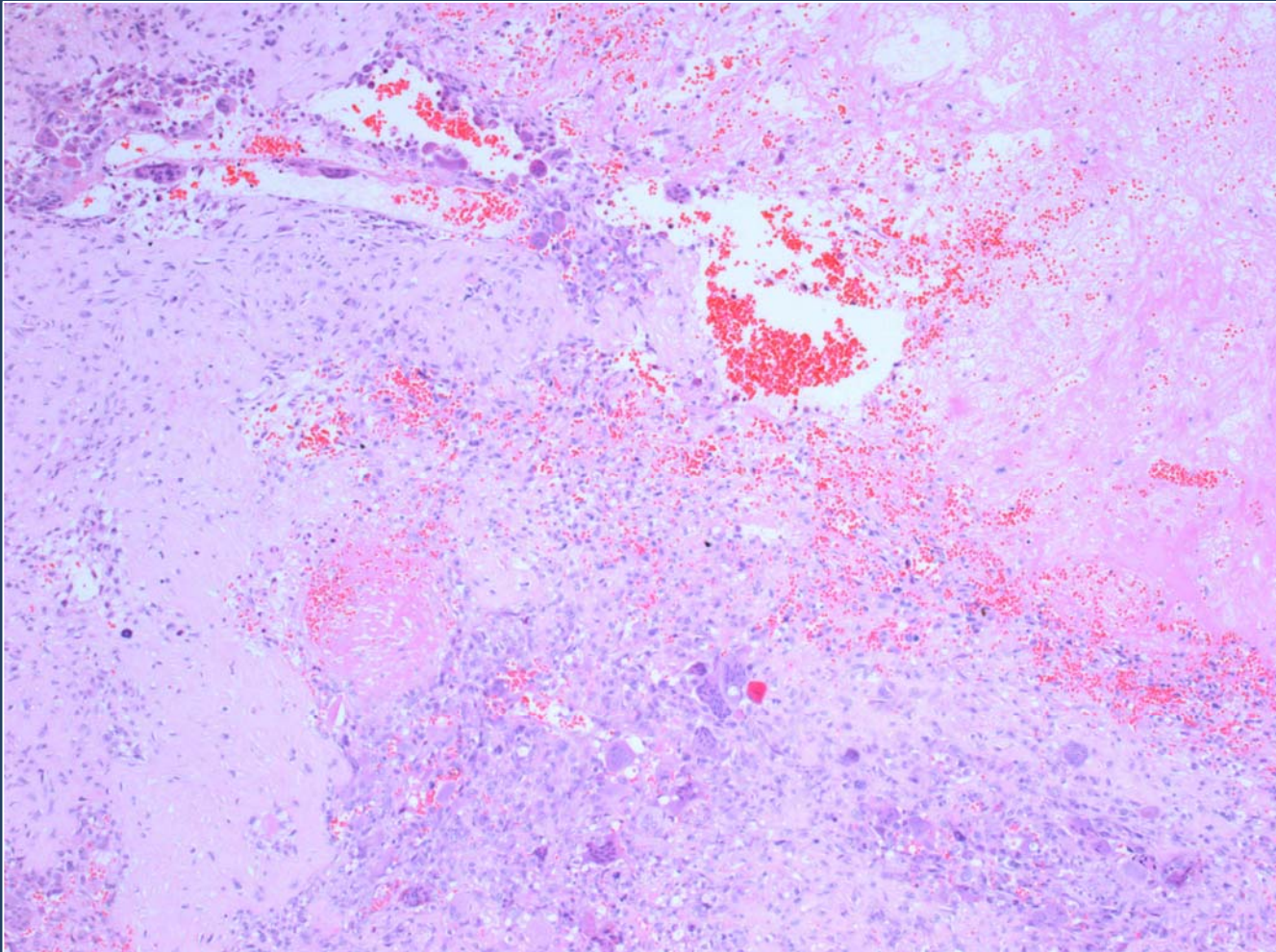


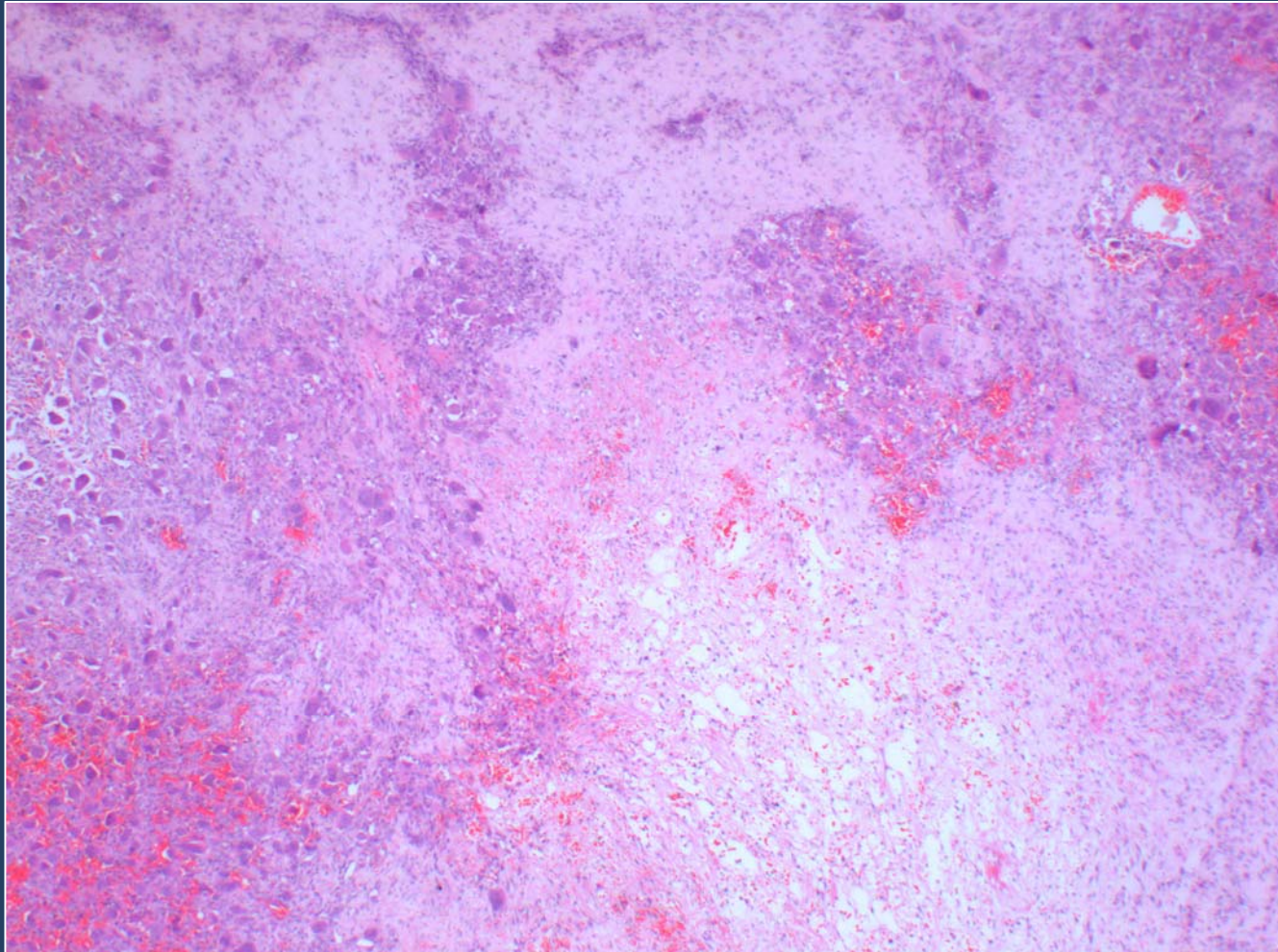
Occasional "atypical" cells



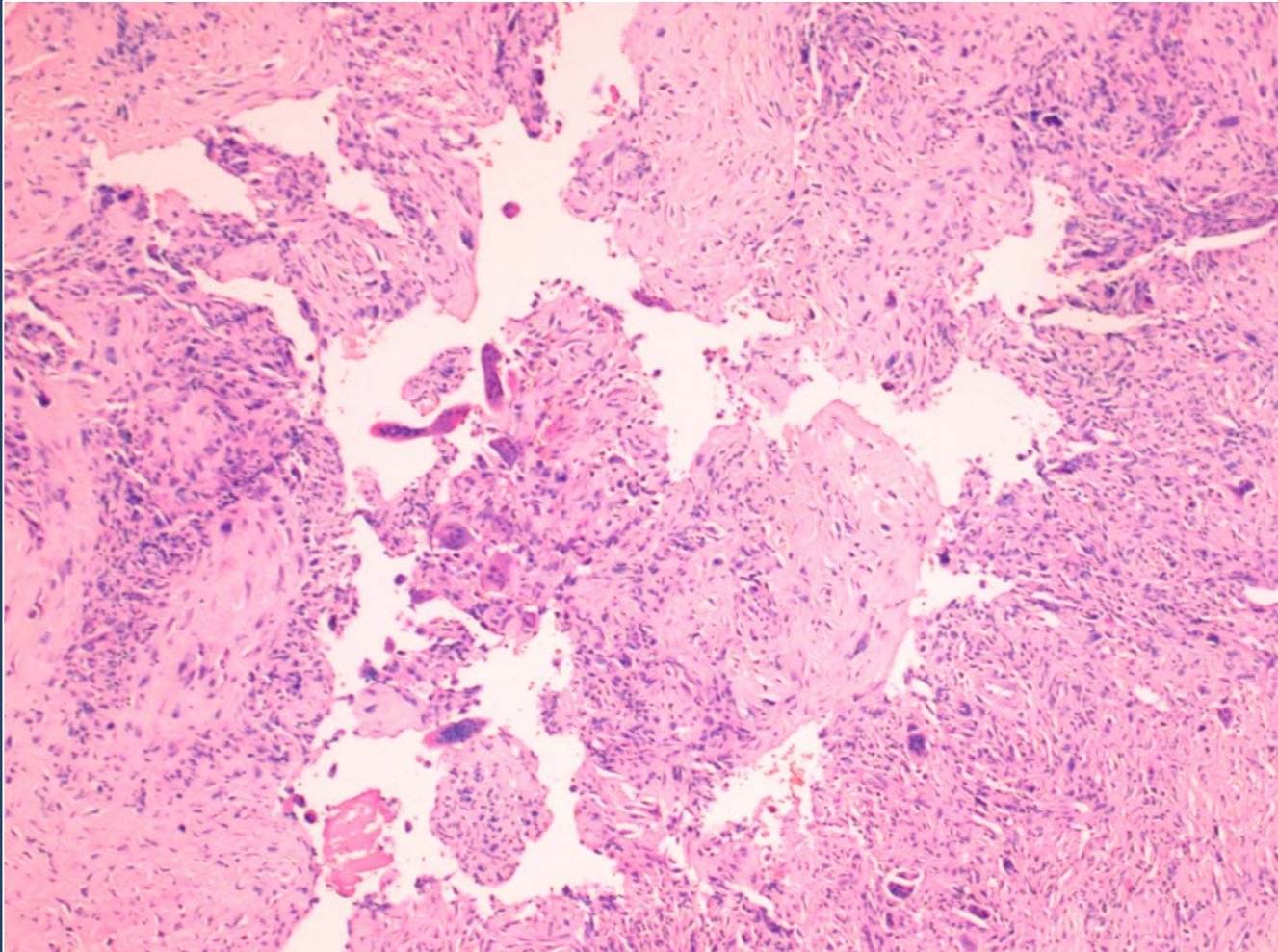


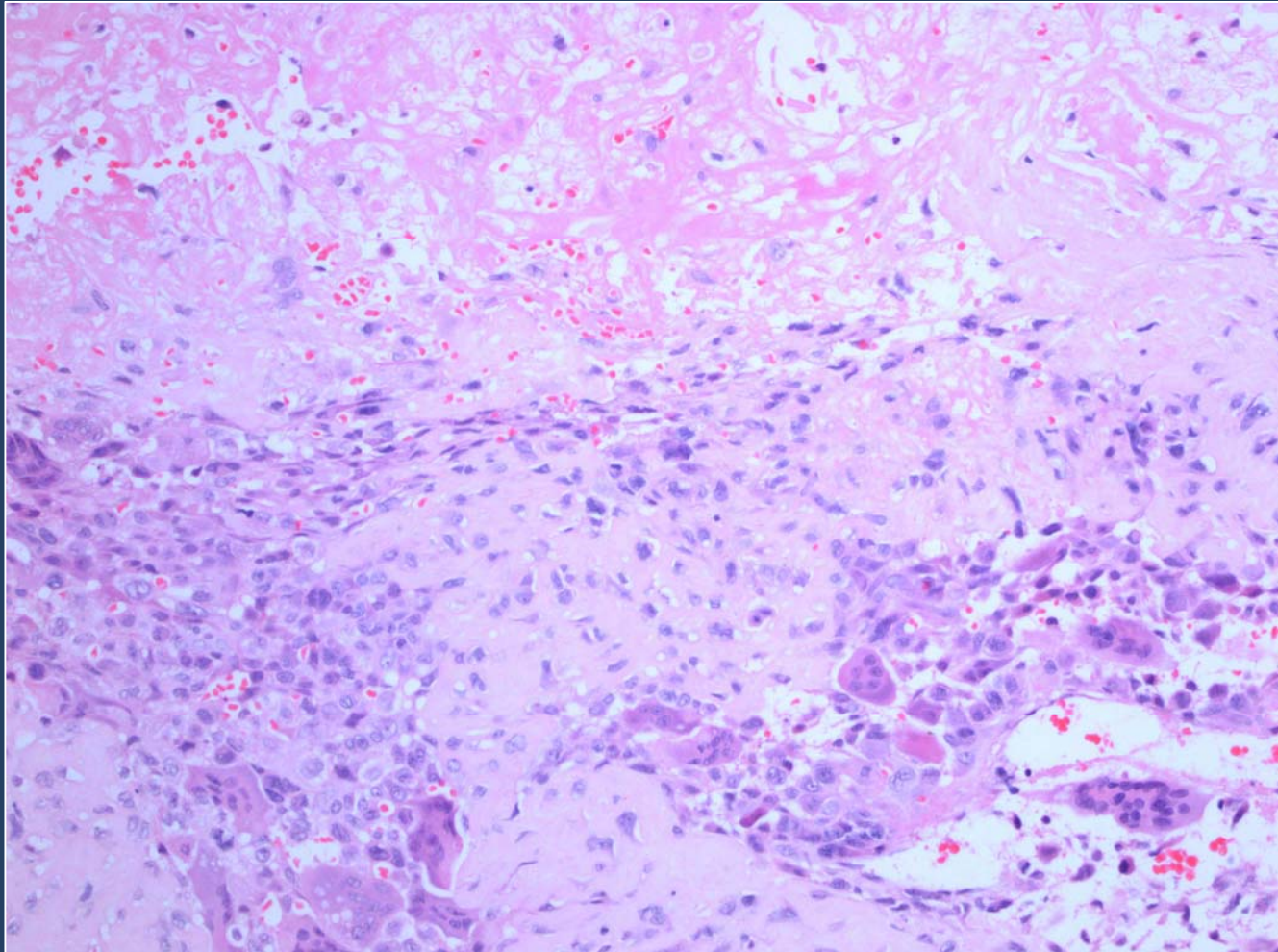
Ischaemic-type necrosis



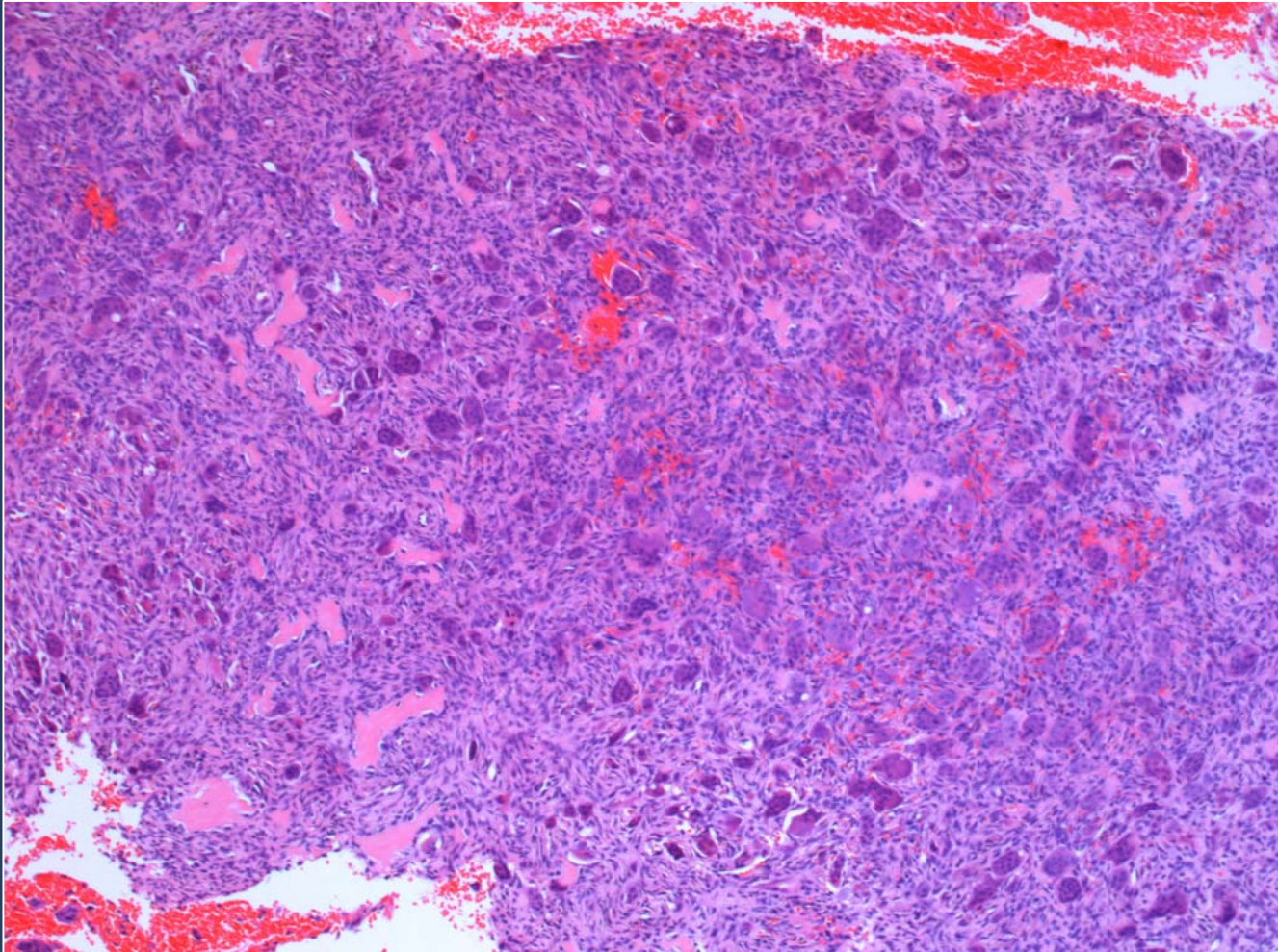


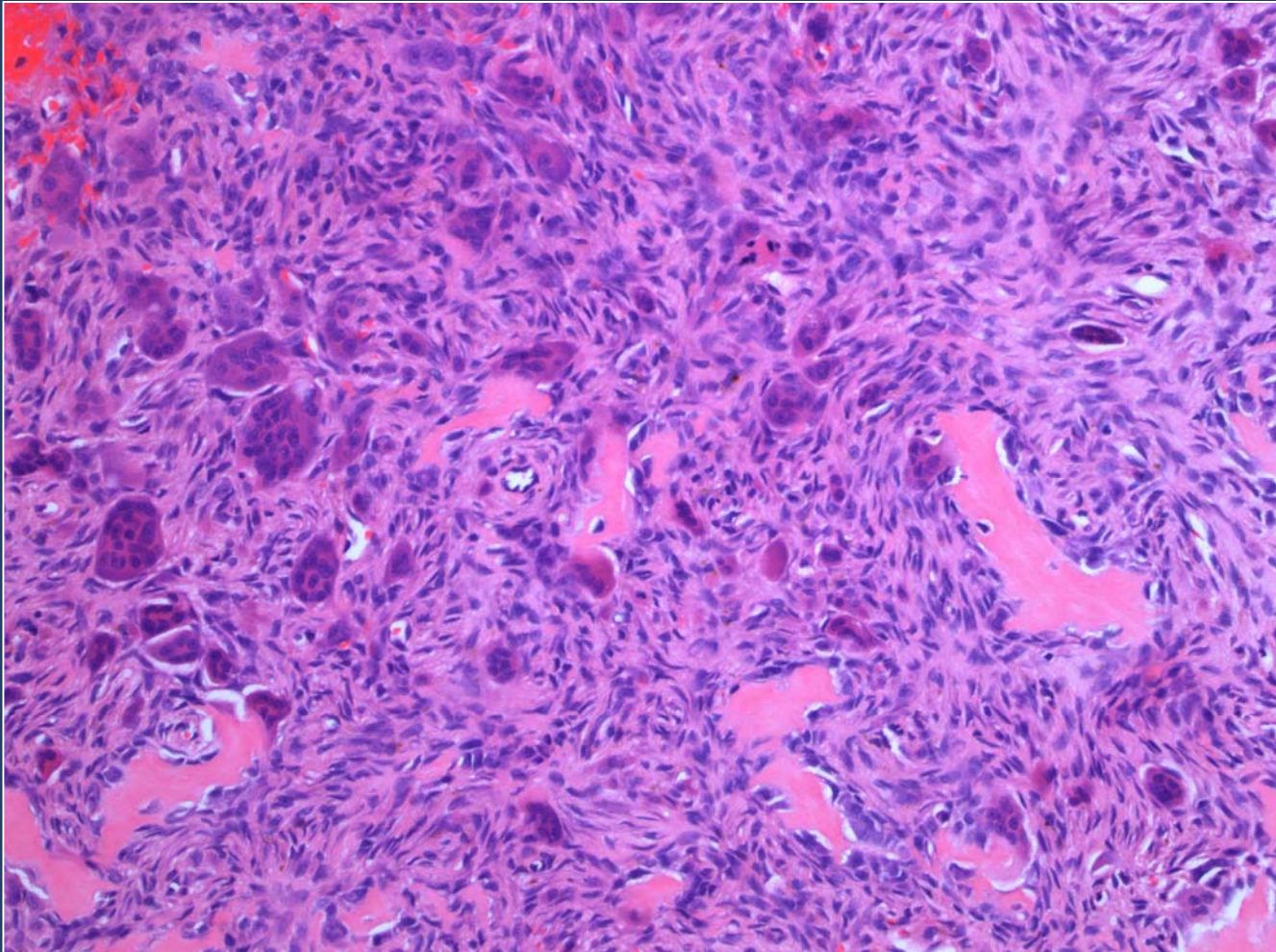
Stromal hyalinisation





Osteoid / bone formation





Distinct *H3F3A* and *H3F3B* driver mutations define chondroblastoma and giant cell tumor of bone

Sam Behjati^{1,2,12}, Patrick S Tarpey^{1,12}, Nadège Presneau^{3,4}, Susanne Scheipl^{3,5}, Nischalan Pillay^{3,6}, Peter Van Loo^{1,7}, David C Wedge¹, Susanna L Cooke¹, Gunes Gundem¹, Helen Davies¹, Serena Nik-Zainal¹, Sancha Martin¹, Stuart McLaren¹, Victoria Goodie¹, Ben Robinson¹, Adam Butler¹, Jon W Teague¹, Dina Halai⁶, Bhavisha Khatri⁶, Ola Myklebost⁸, Daniel Baumhoer⁹, Gernot Jundt⁹, Rifat Hamoudi^{3,4}, Roberto Tirabosco⁶, M Fernanda Amary⁶, P Andrew Futreal¹, Michael R Stratton¹, Peter J Campbell^{1,10,11} & Adrienne M Flanagan^{3,4,6}

ORIGINAL ARTICLE

OPEN

H3F3A (Histone 3.3) G34W Immunohistochemistry *A Reliable Marker Defining Benign and Malignant Giant Cell Tumor of Bone*

Fernanda Amary, MD, PhD,† Fitim Berisha, MSc,* Hongtao Ye, PhD,* Manu Gupta, PhD,†
Alice Gutteridge, MSc,† Daniel Baumhoer, MD, PhD,‡ Rebecca Gibbons, BSc,*
Roberto Tirabosco, MD,* Paul O'Donnell, MD,* and Adrienne M. Flanagan, MD, PhD*†*

The Journal of Pathology: Clinical Research

J Path: Clin Res April 2015; **1**: 113–123

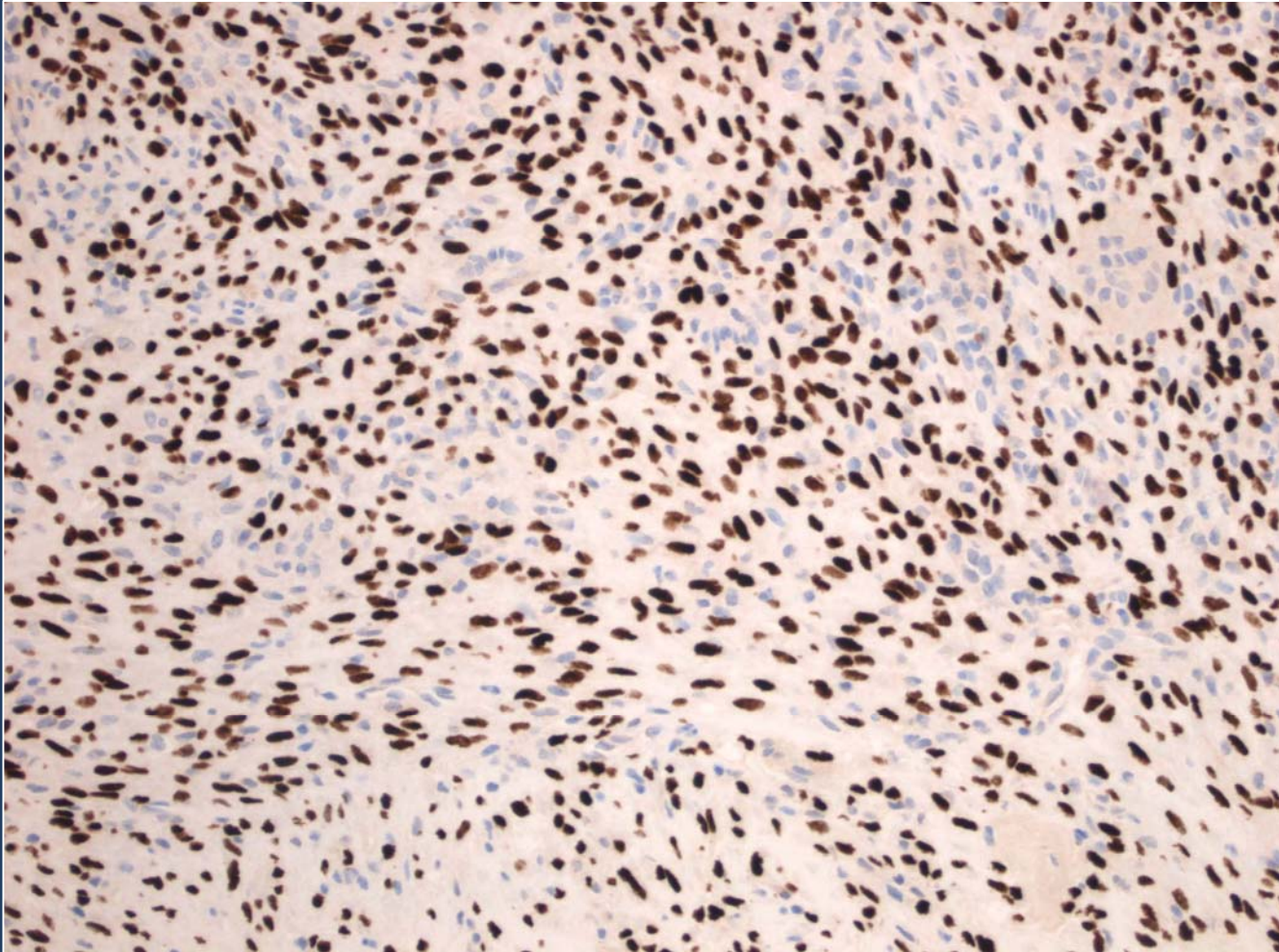
Published online 16 March 2015 in Wiley Online Library
(wileyonlinelibrary.com). DOI: 10.1002/cjp2.13

Original Article

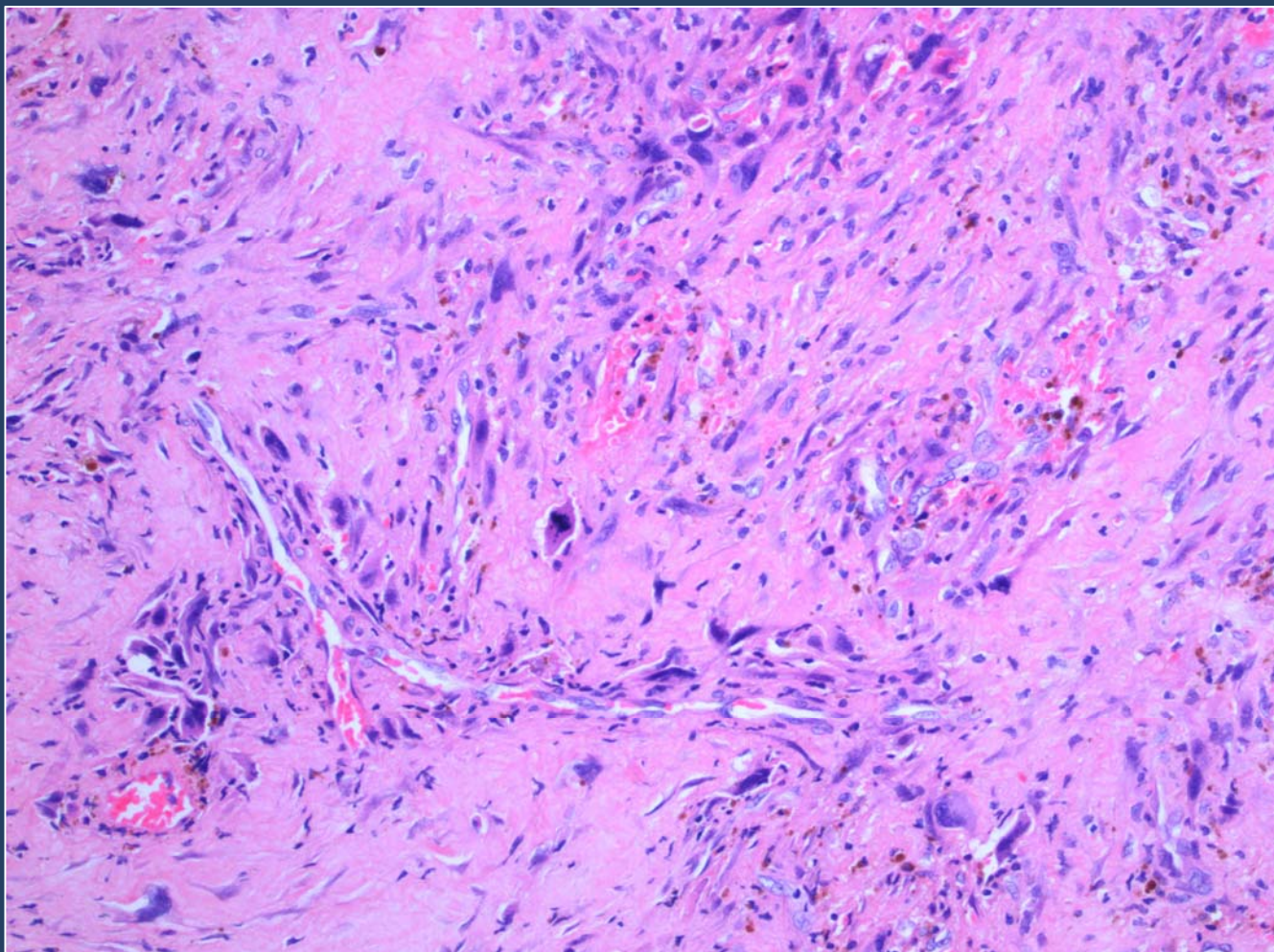
Diagnostic value of *H3F3A* mutations in giant cell tumour of bone compared to osteoclast-rich mimics

Nadège Presneau,^{1,2††} Daniel Baumhoer,^{3†} Sam Behjati,⁴ Nischalan Pillay,⁵ Patrick Tarpey,⁴ Peter J Campbell,⁴ Gernot Jundt,³ Rifat Hamoudi,^{1,2§} David C Wedge,⁴ Peter Van Loo,^{4,6} A Bassim Hassan,⁷ Bhavisha Khatri,⁵ Hongtao Ye,⁵ Roberto Tirabosco,⁵ M Fernanda Amary⁵ and Adrienne M Flanagan^{1,2,5*}

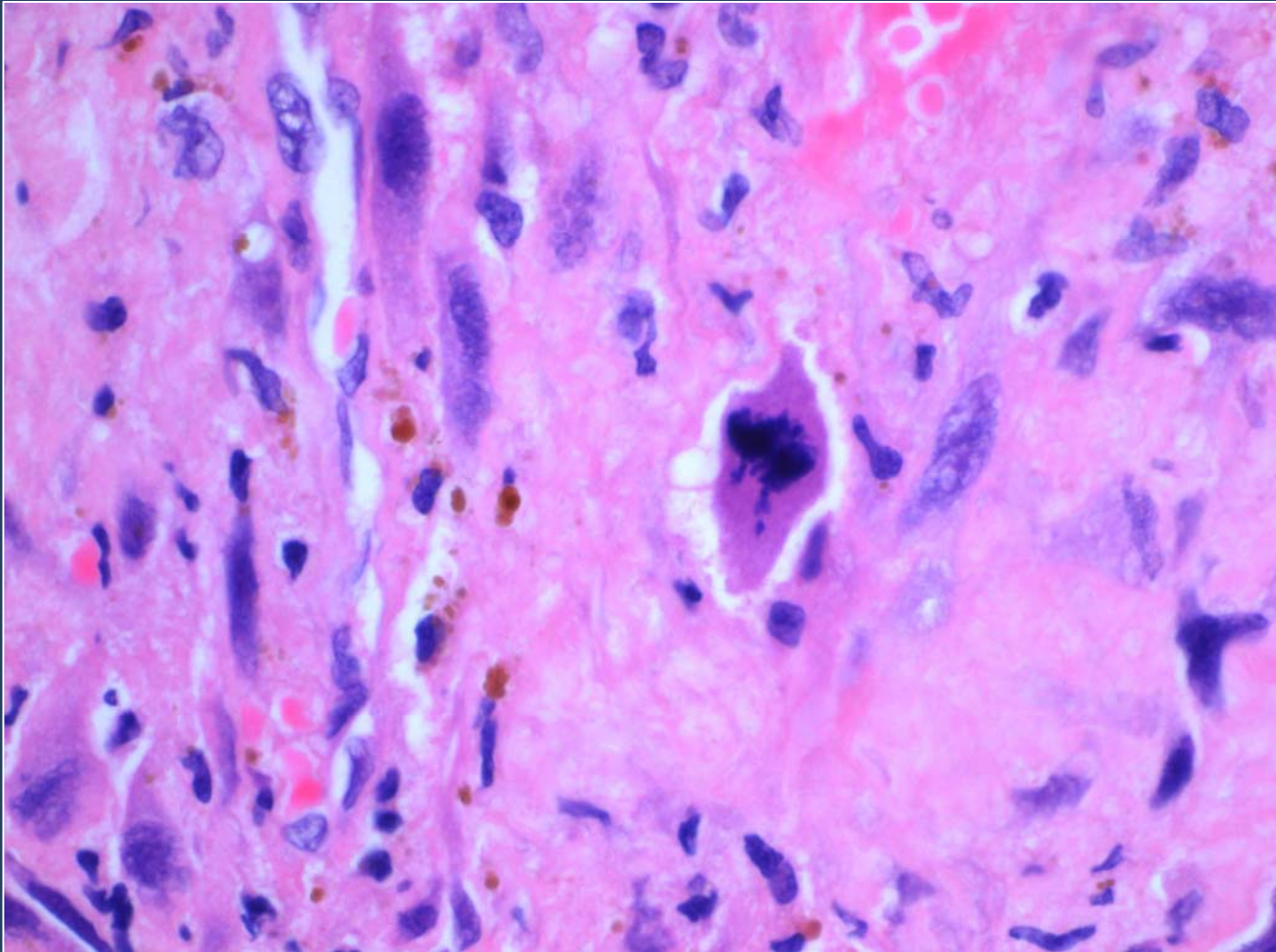
G34W



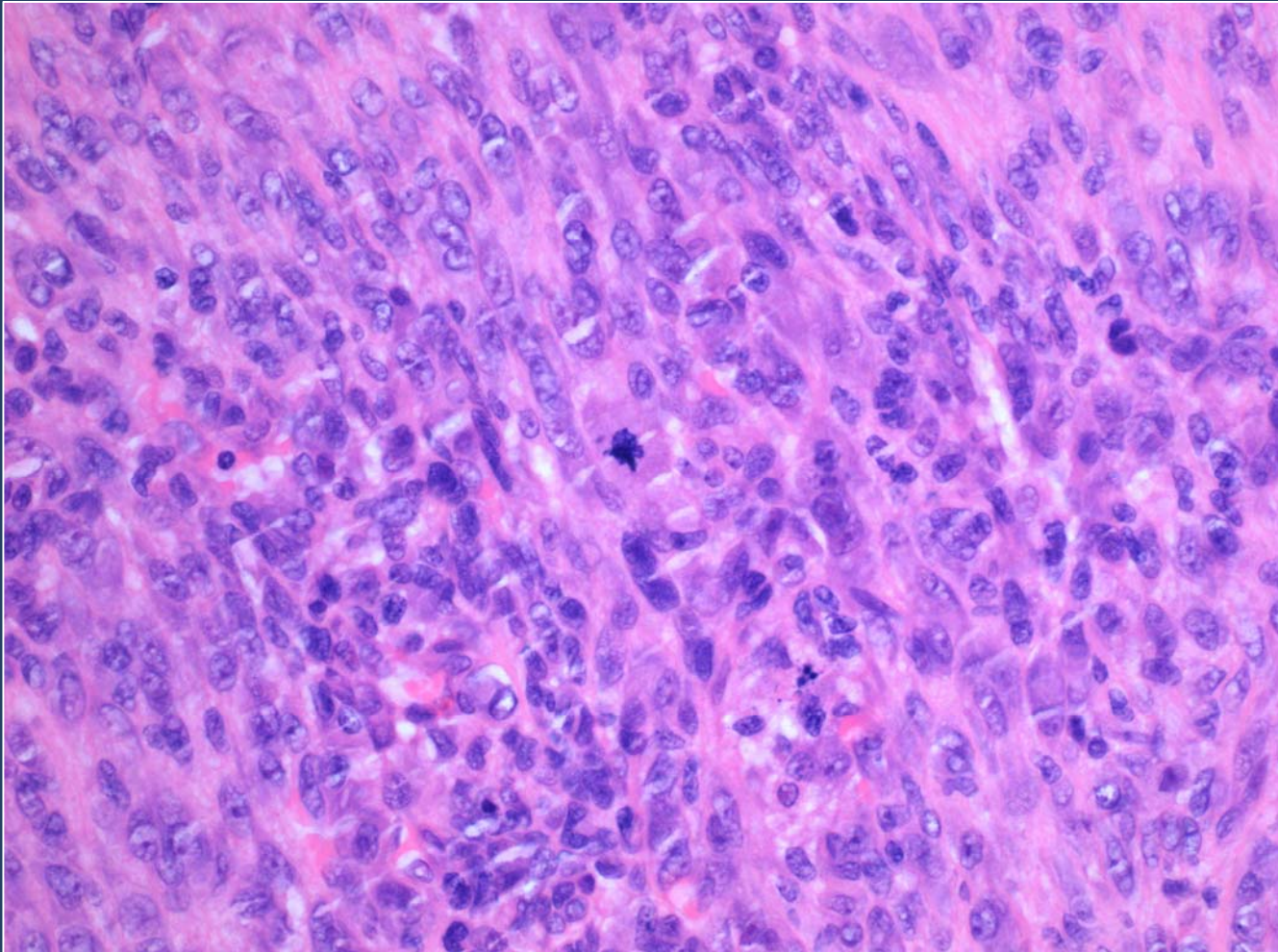
Malignant GCT



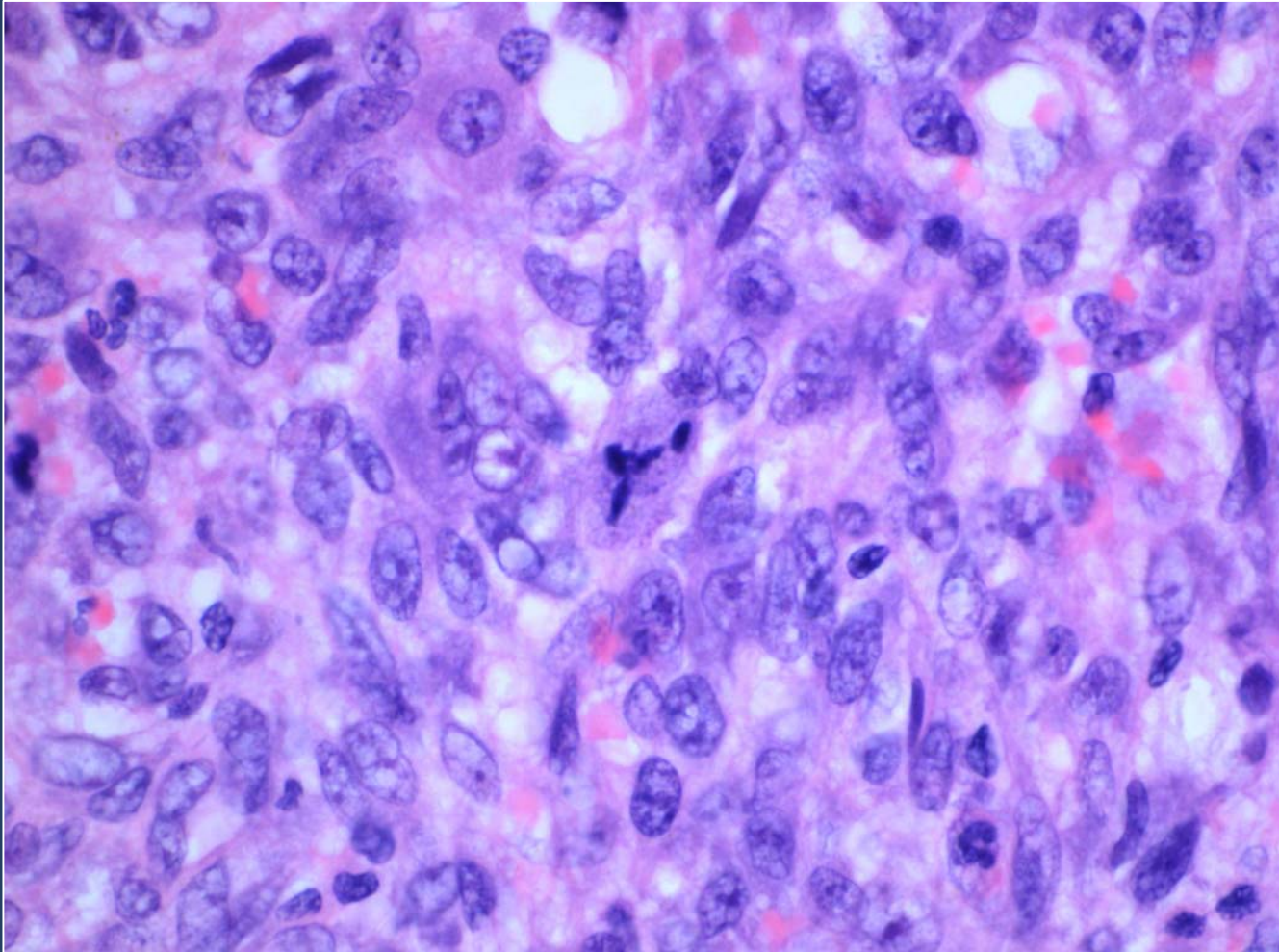
Malignant GCT



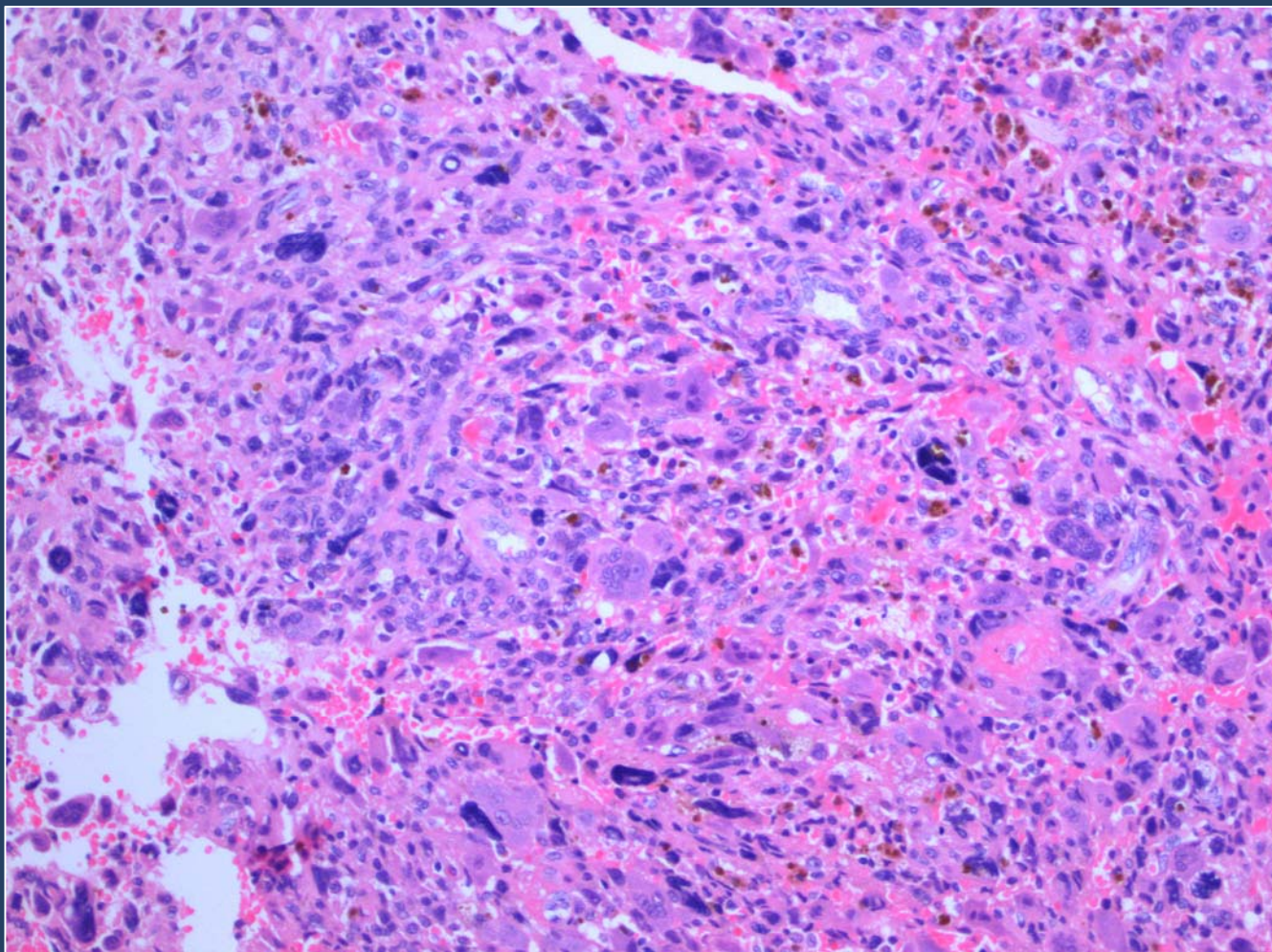
Malignant GCT



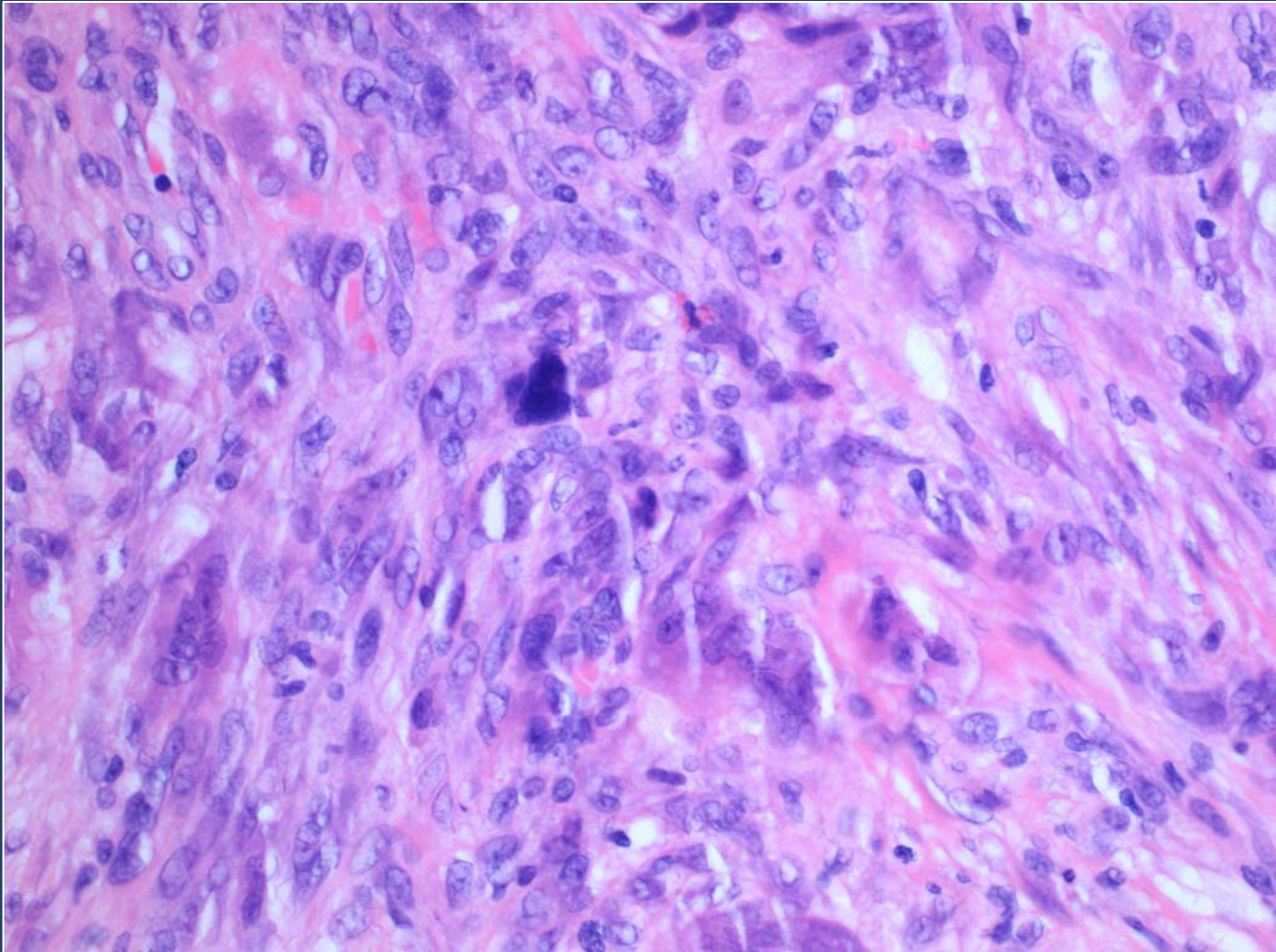
Malignant GCT



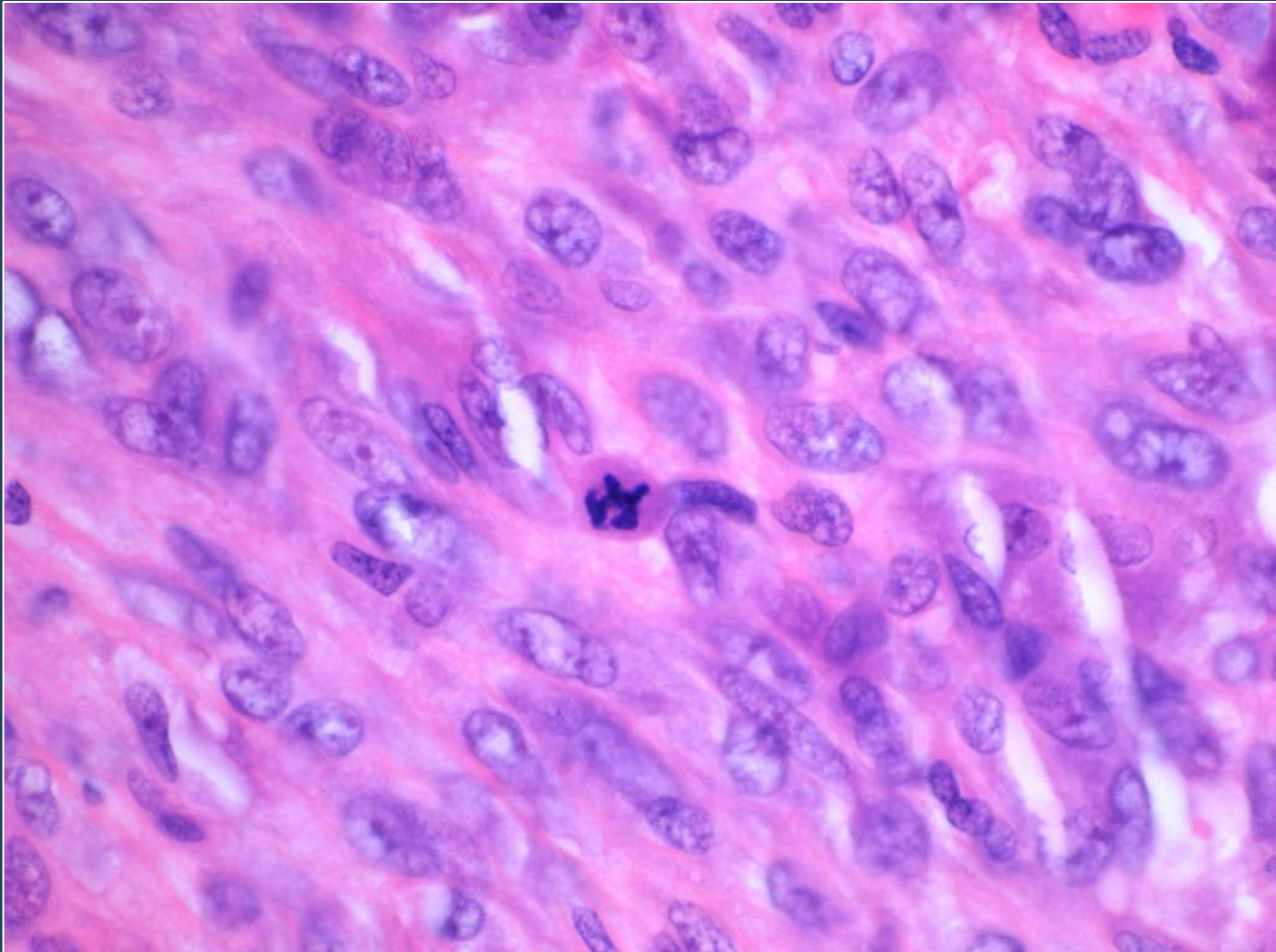
Malignant GCT



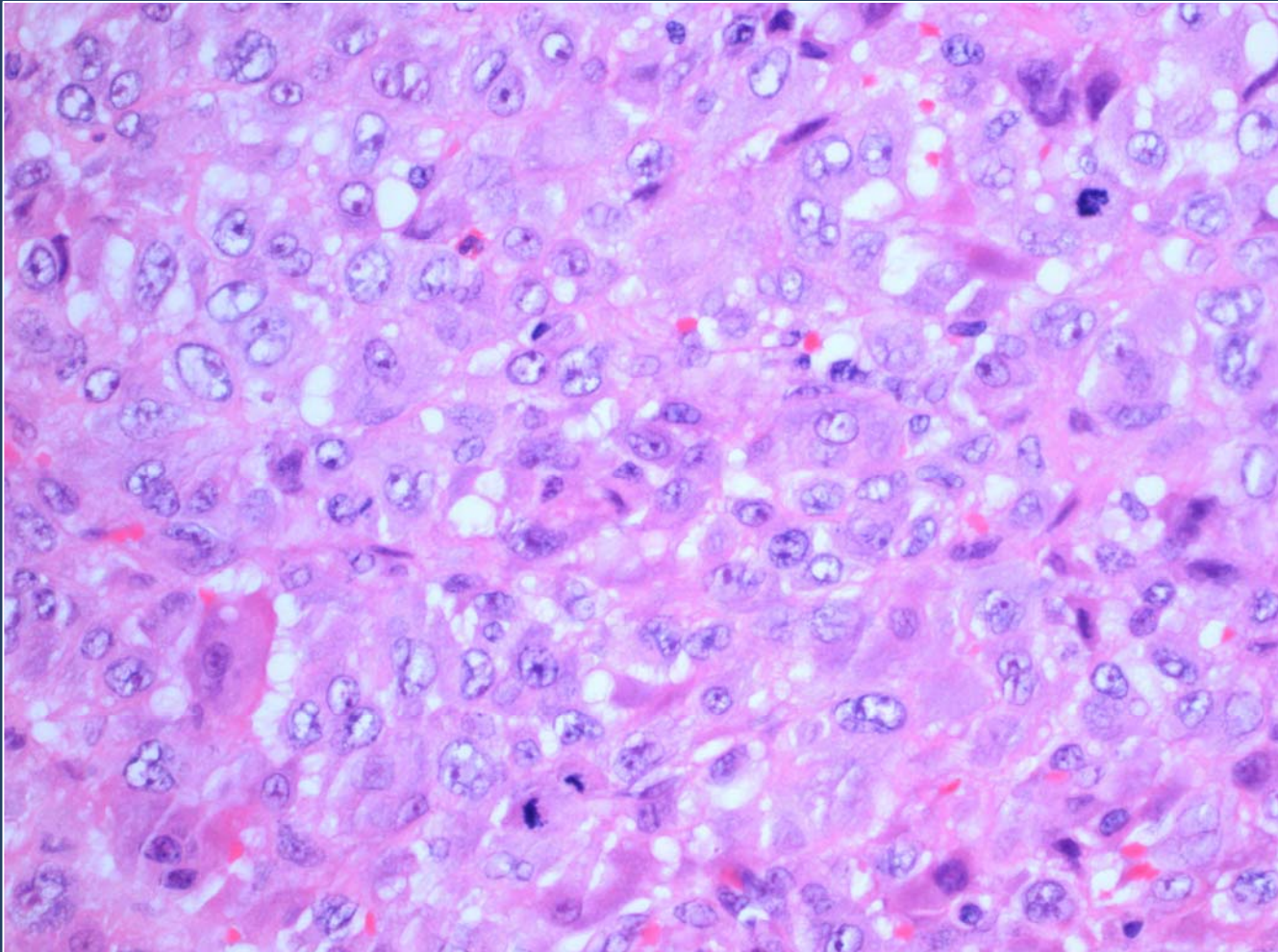
Malignant GCT



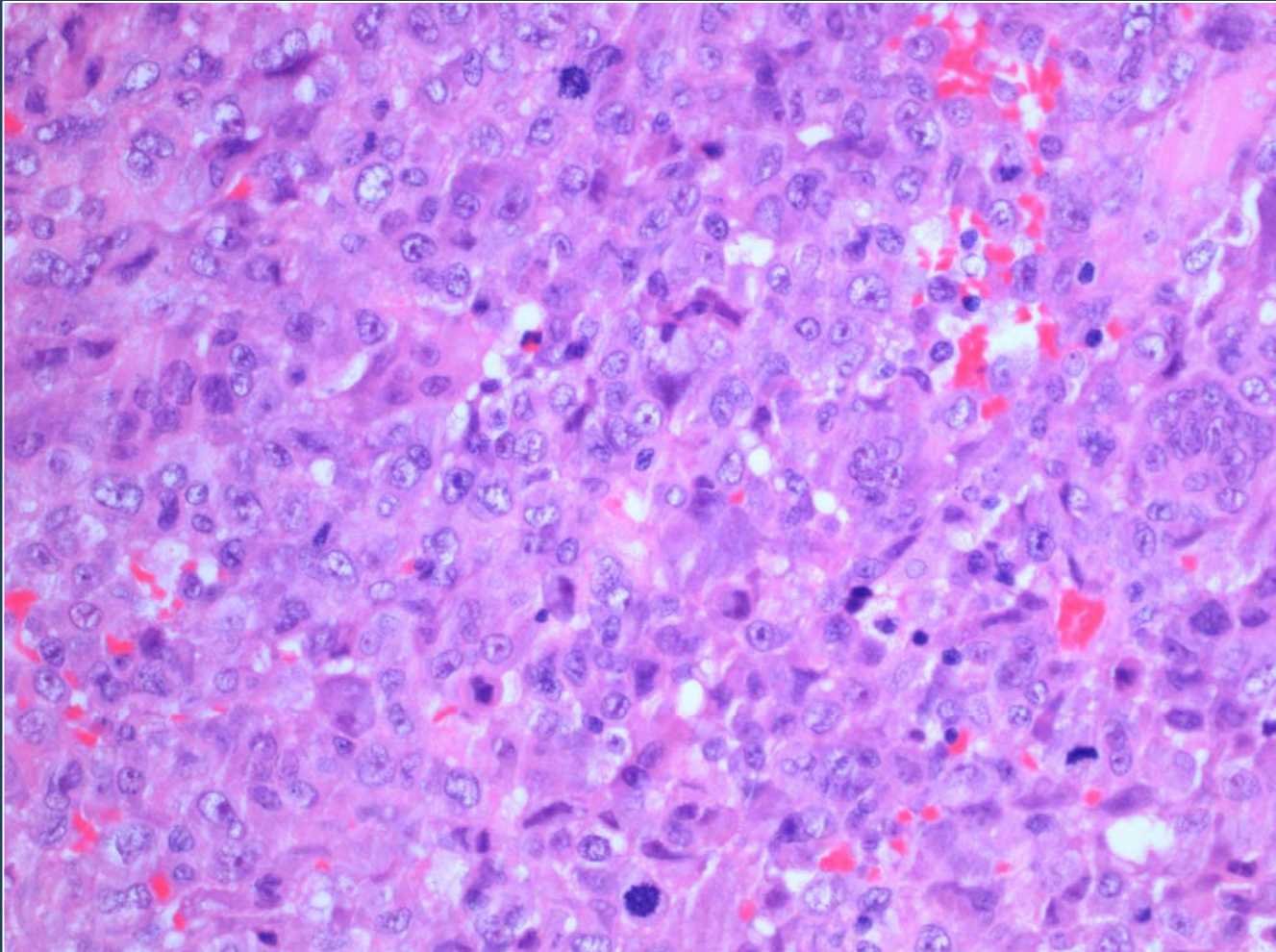
Malignant GCT



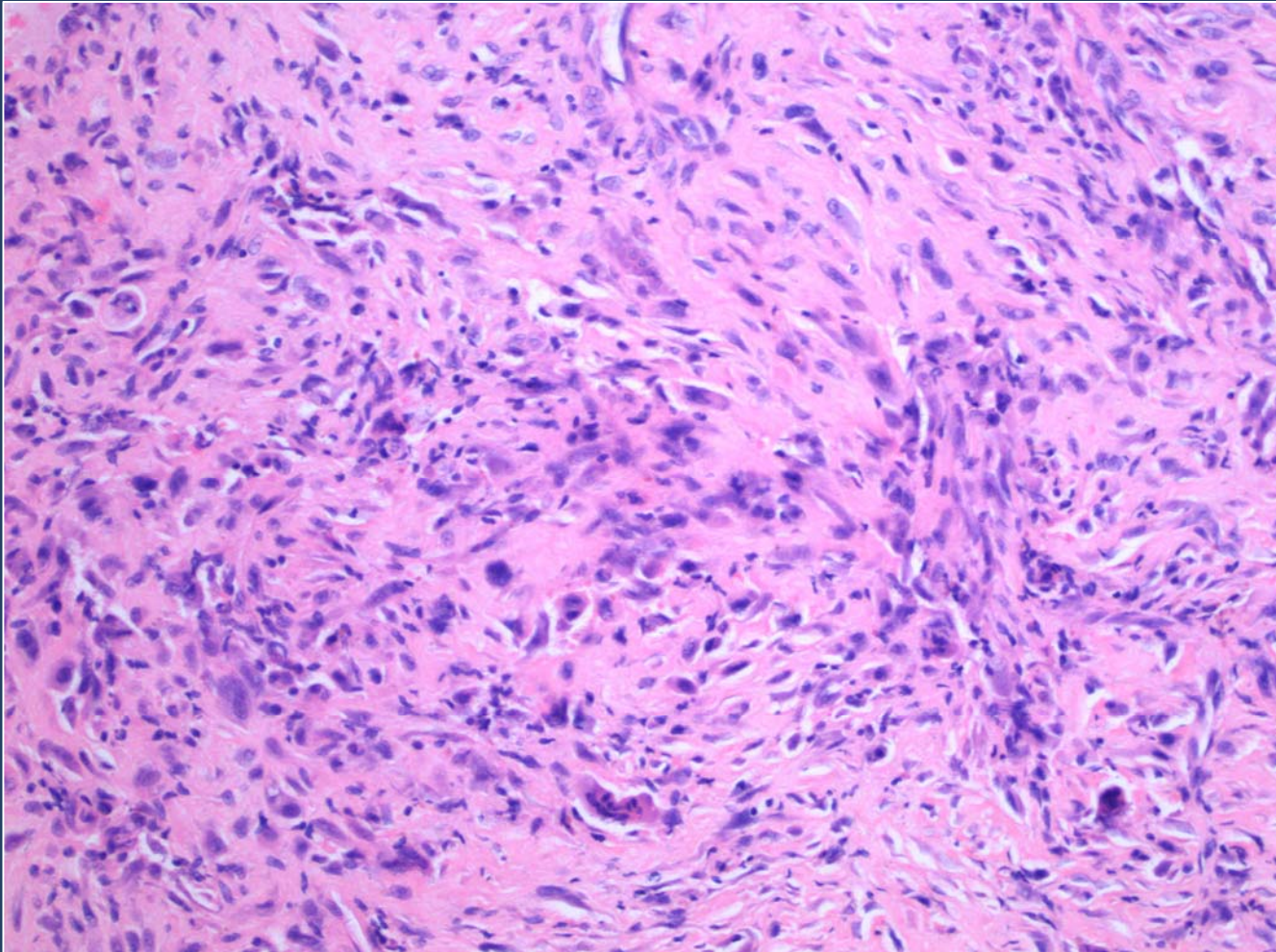
Malignant GCT



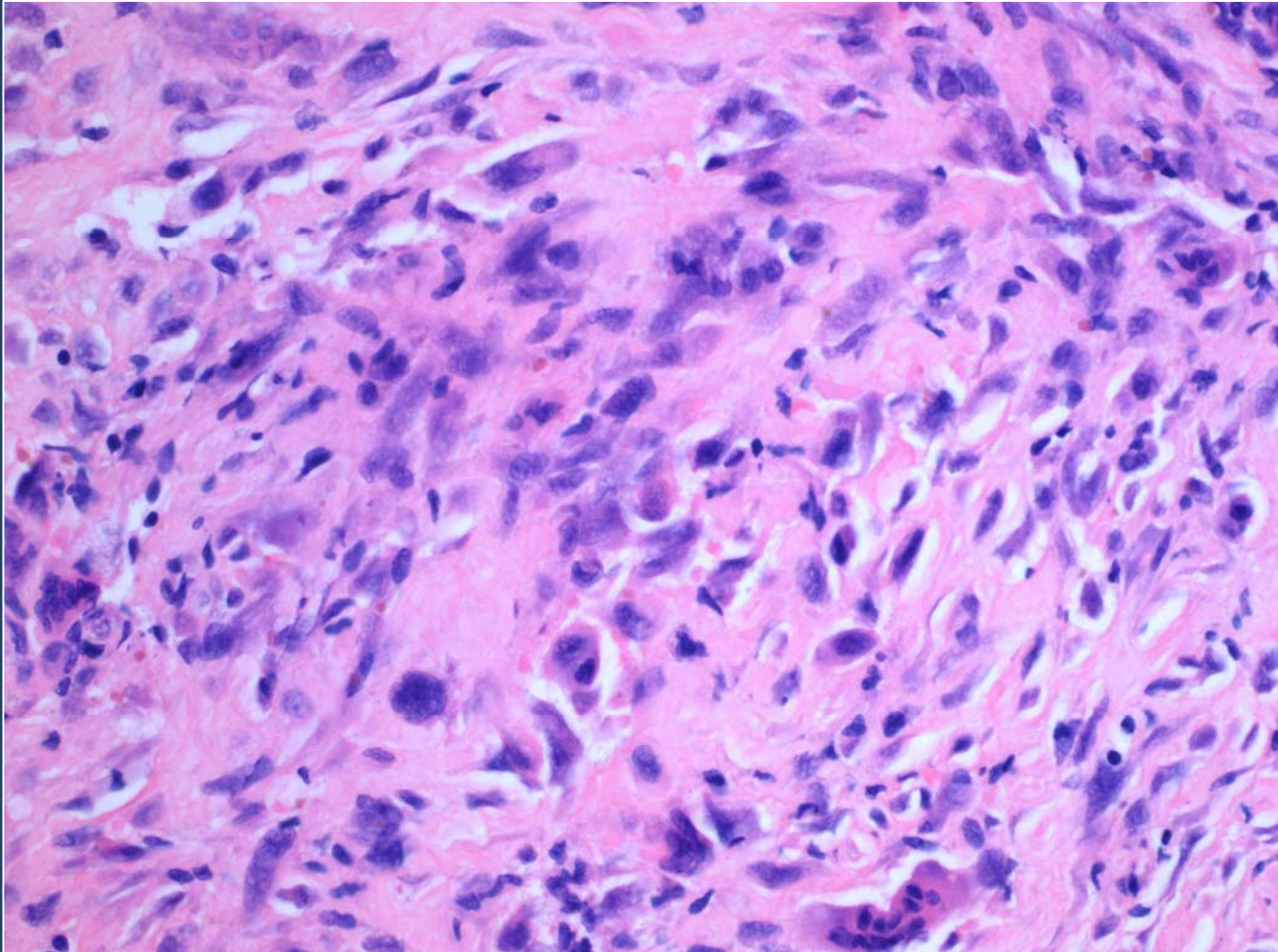
Malignant GCT



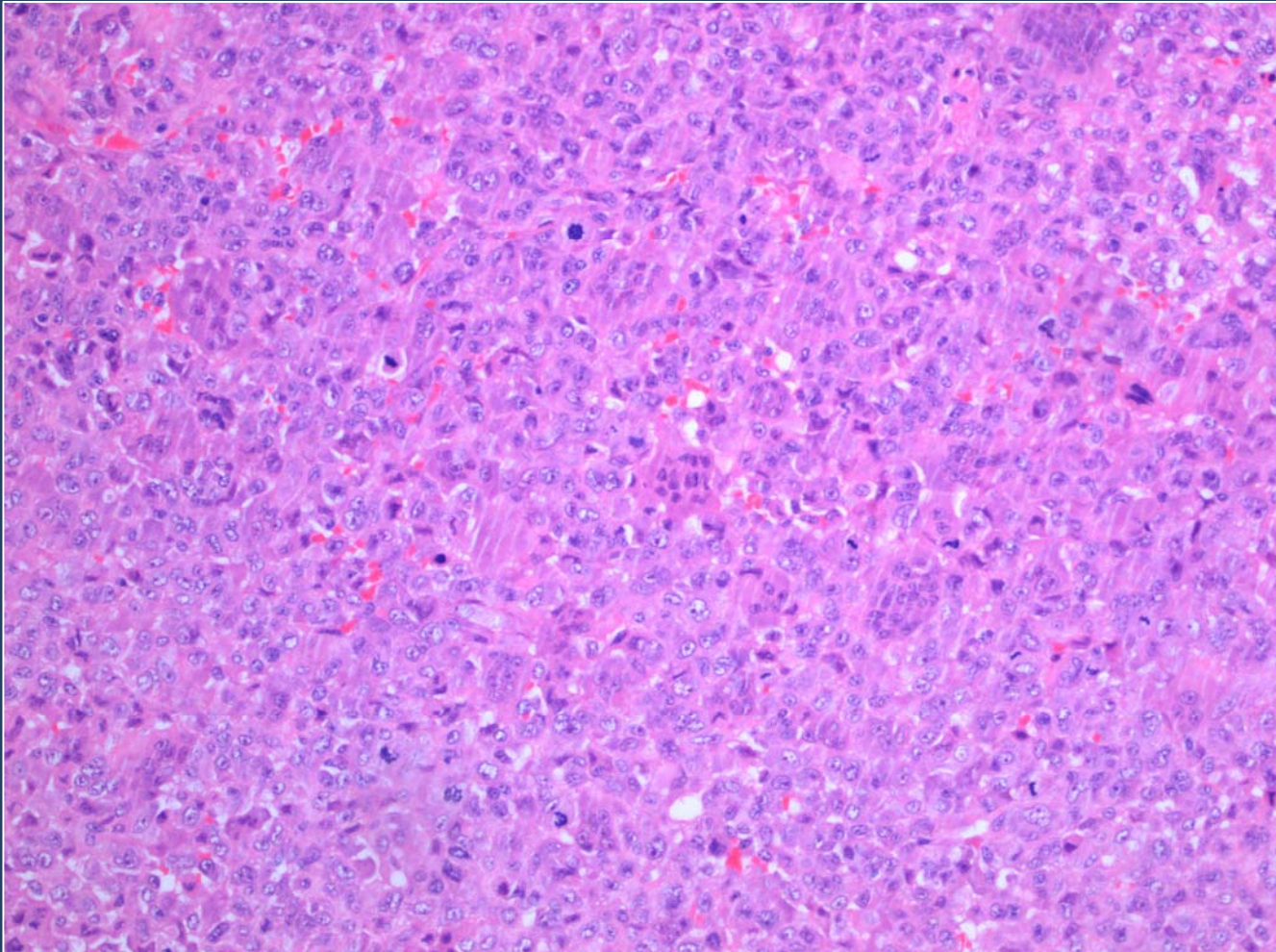
Malignant GCT

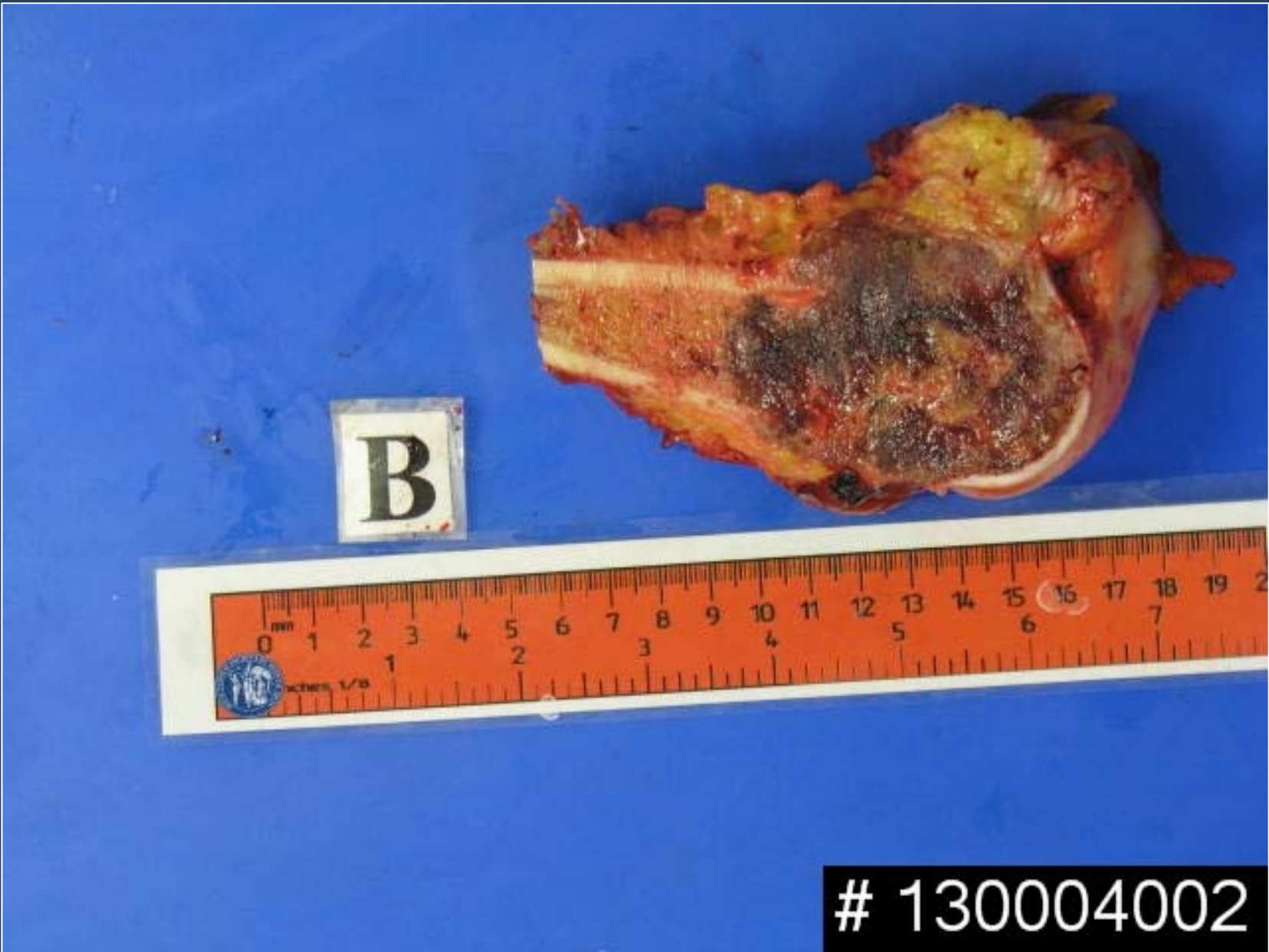

Malignant GCT



Malignant GCT



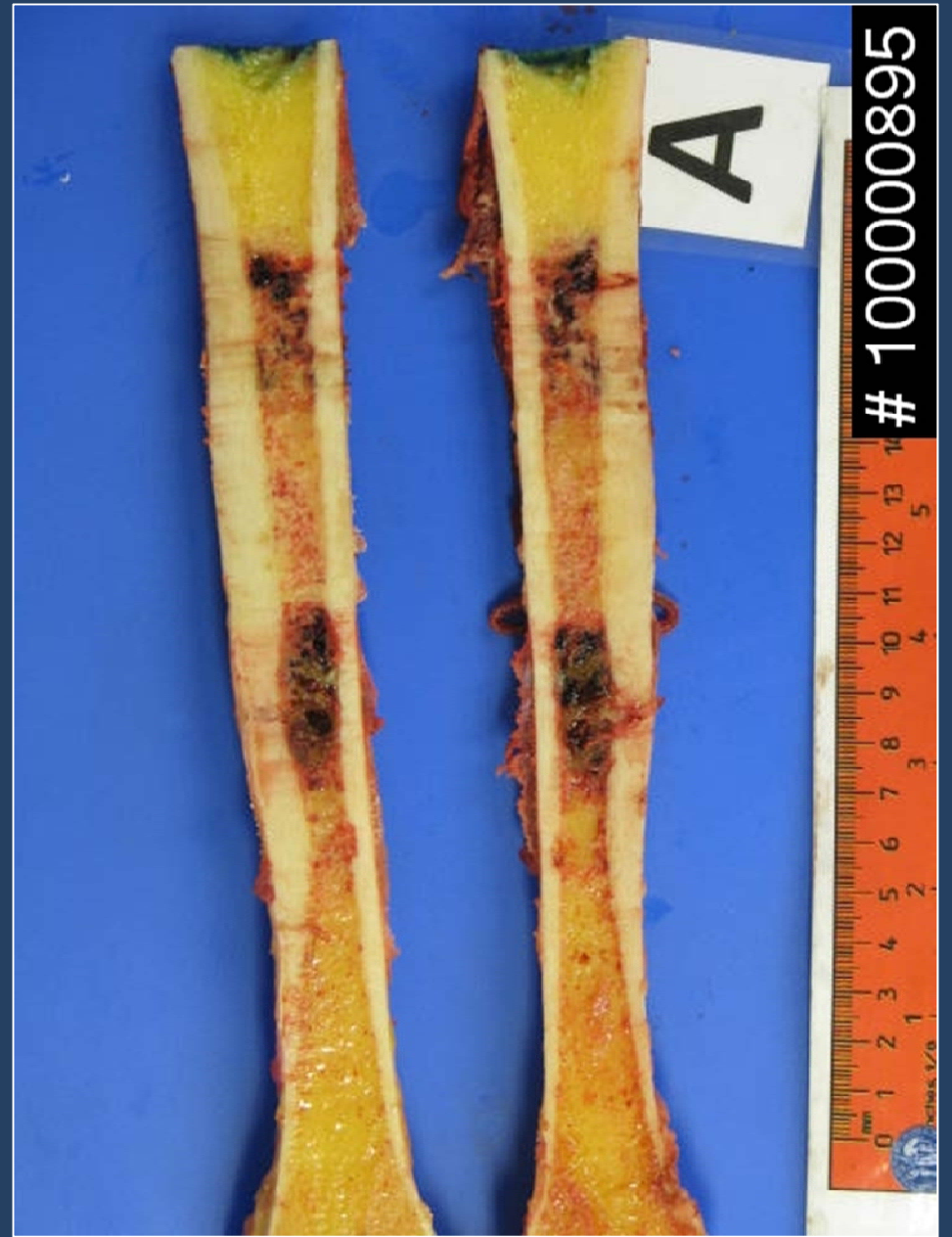
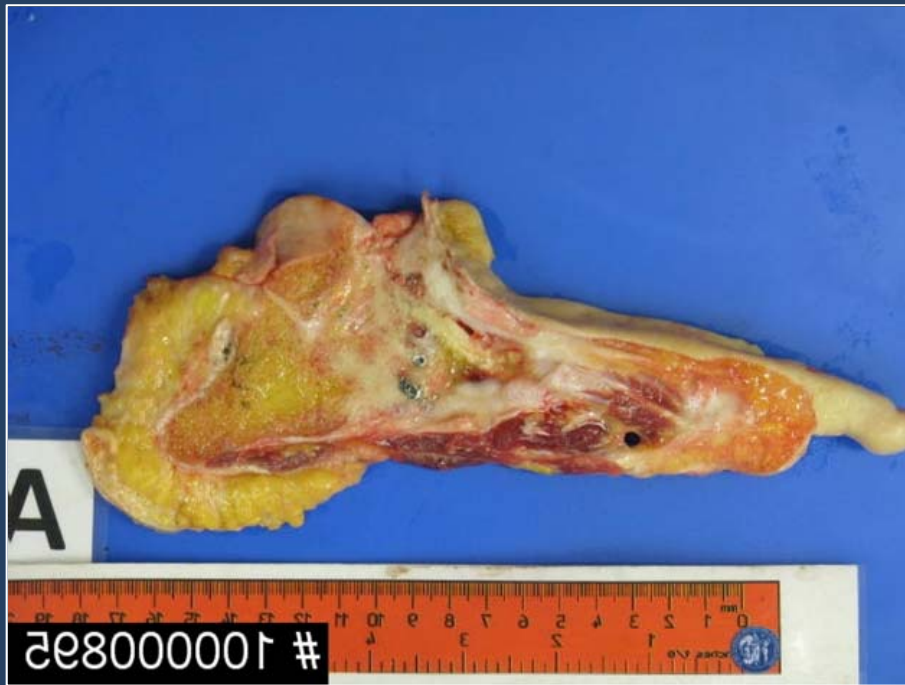
130004002

Malignant Giant Cell Tumour of Bone

Metastatic

Primary



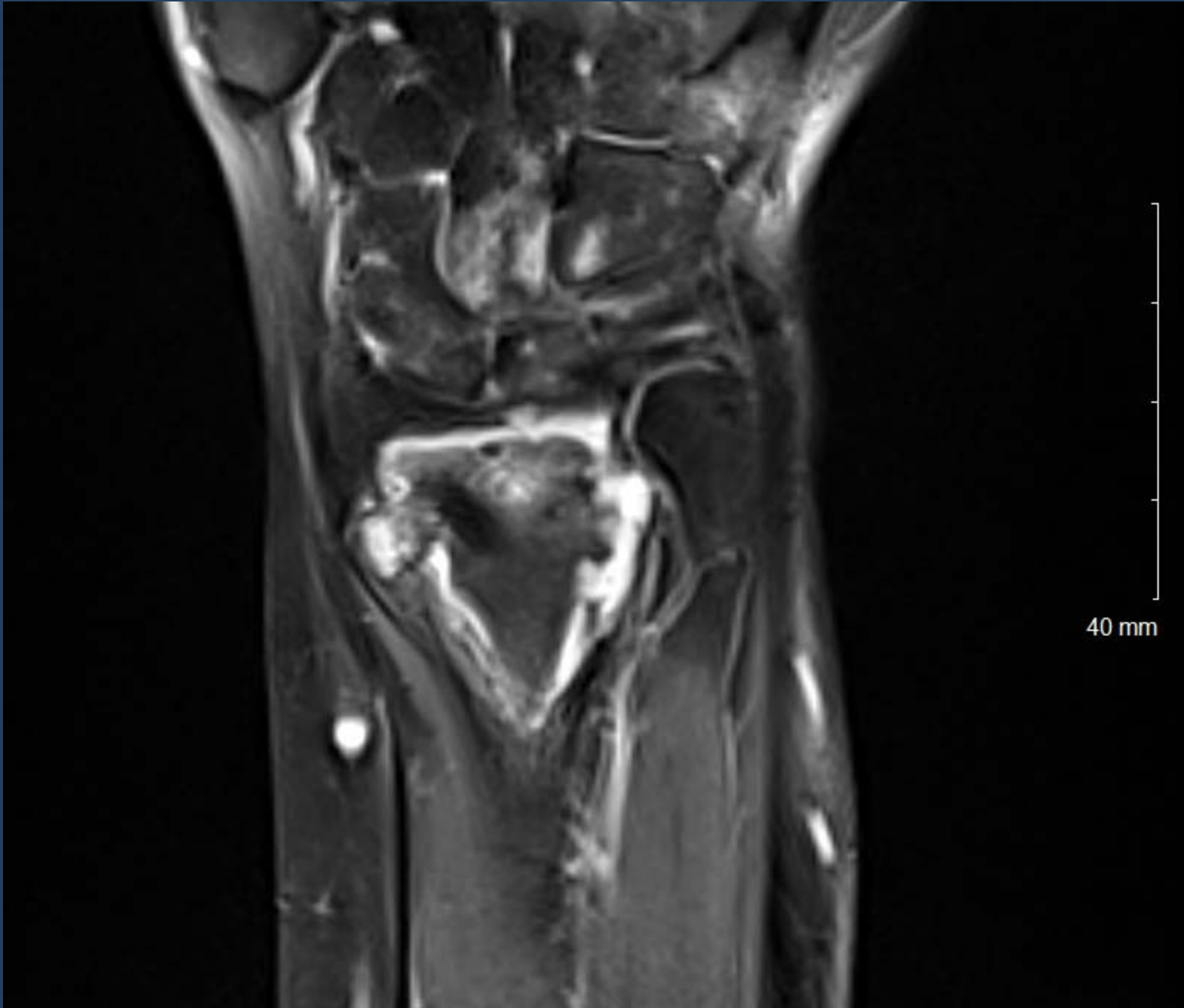
Clinical Notes *14 year-old Female*

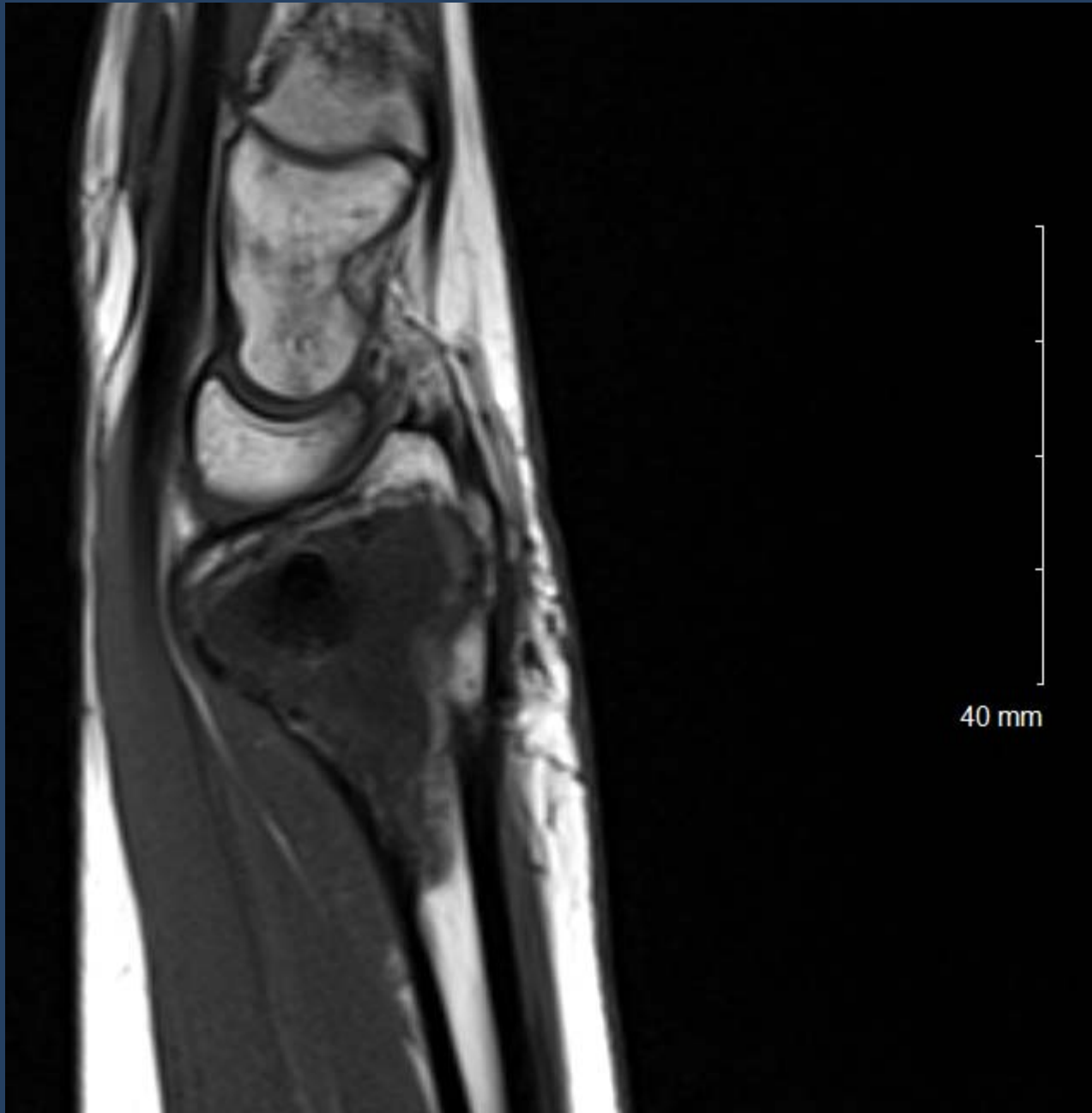Jan 2017. Presenting with spontaneous fracture of left wrist.

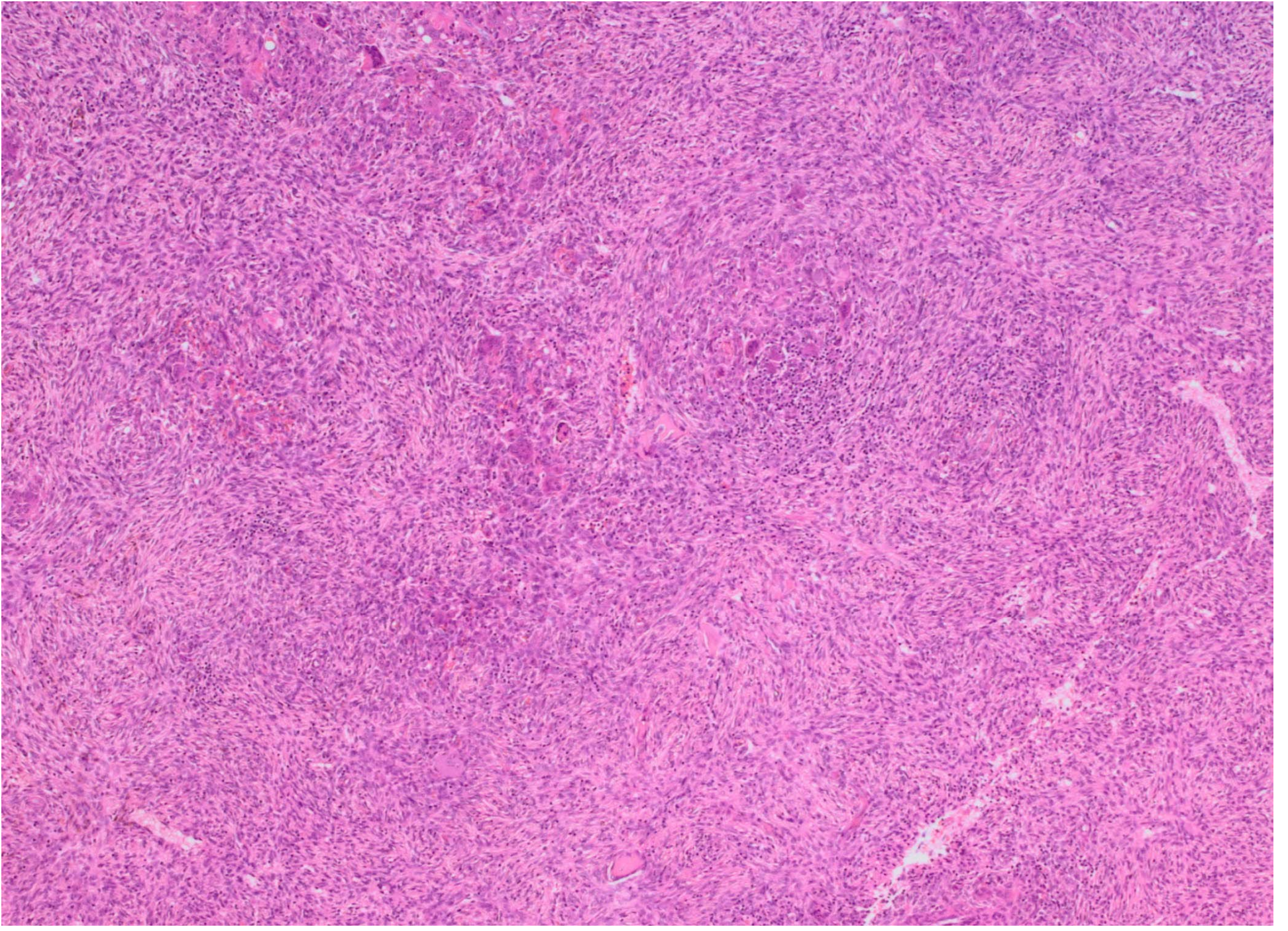
Imaging shown a 35x25mm, well-defined expansile, intramedullary lytic lesion on the left distal radius.

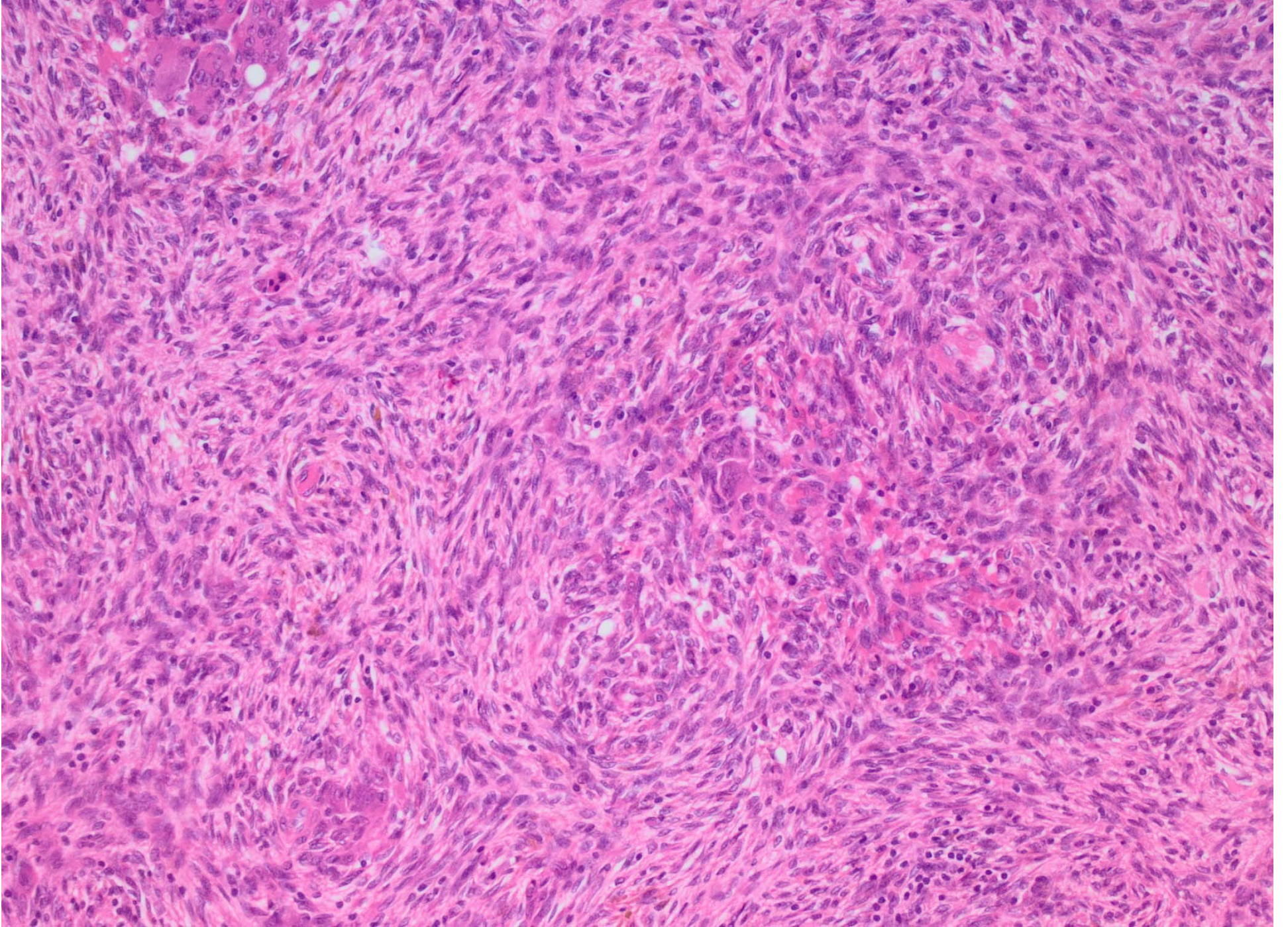
Open biopsy reported as Giant Cell Tumour of Bone.

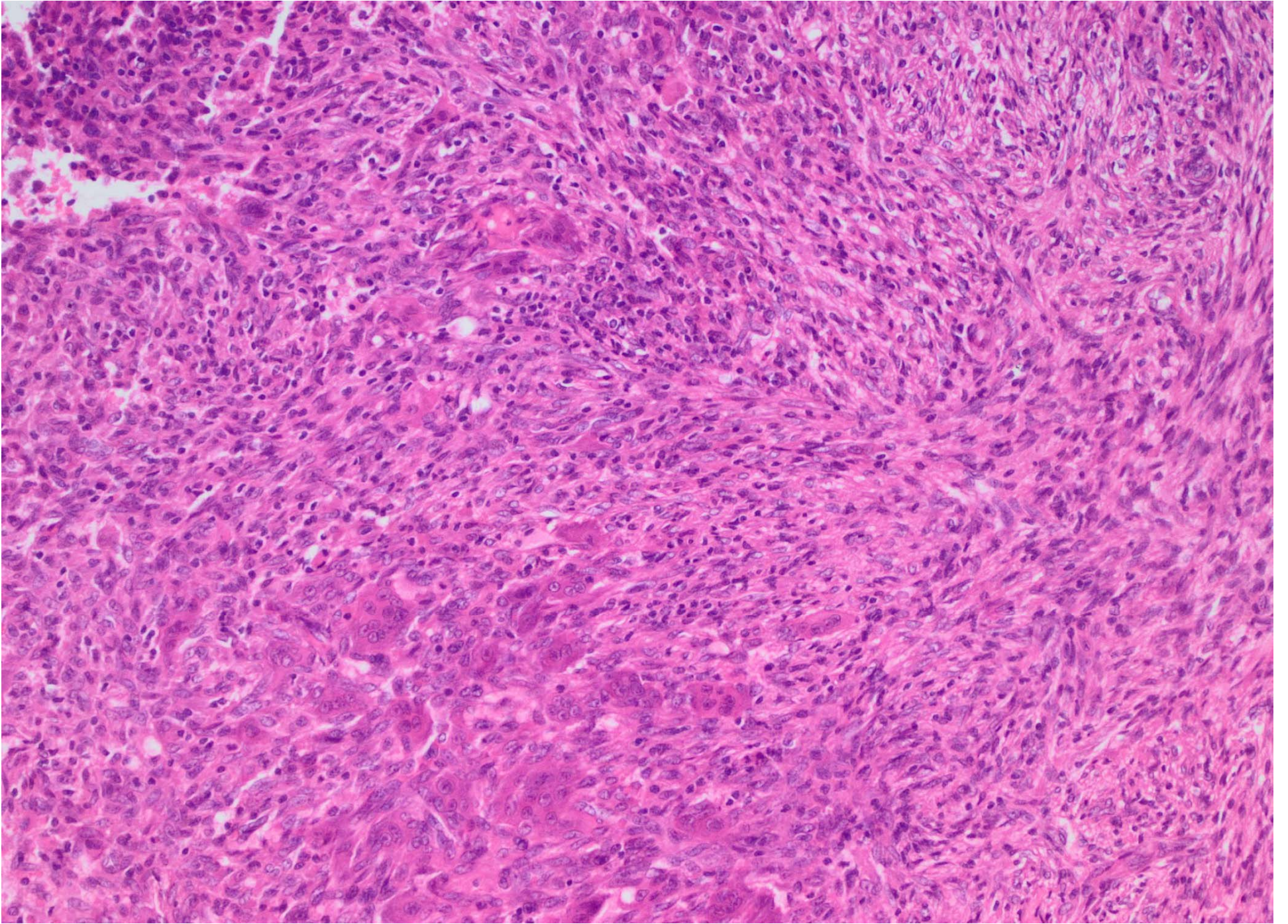
Mar 2017. Distal radius replacement. Diagnosis confirmed.

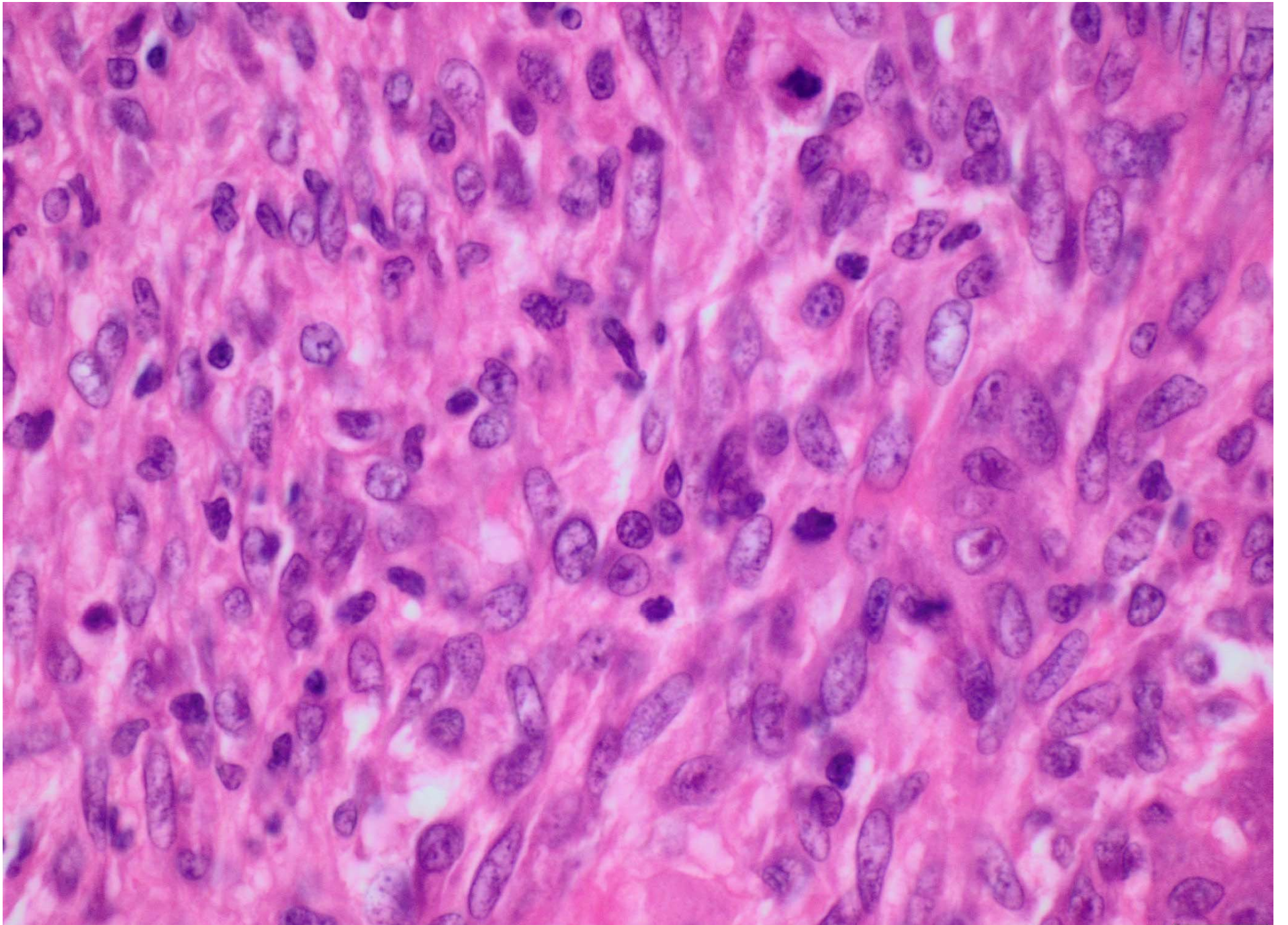


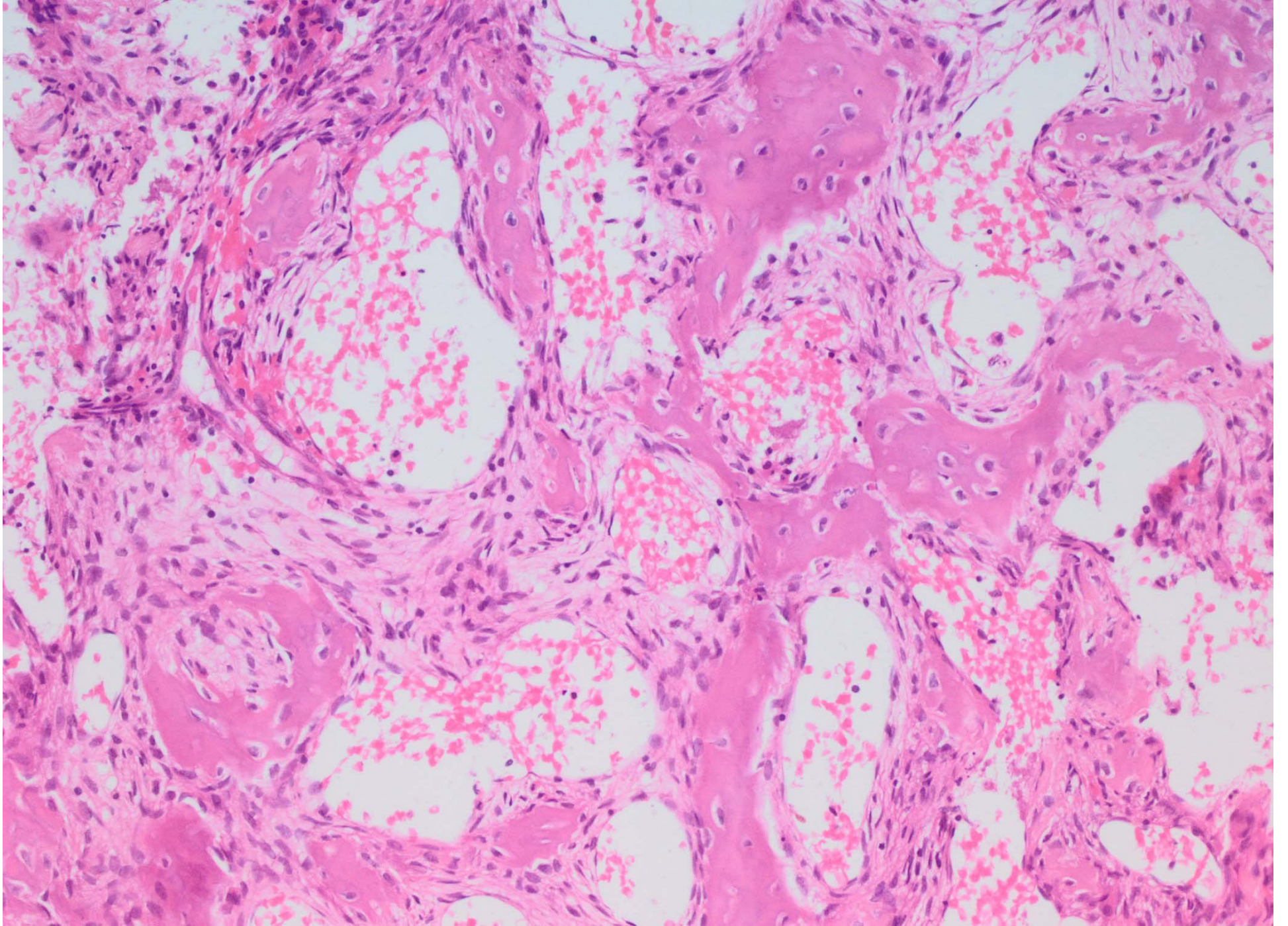


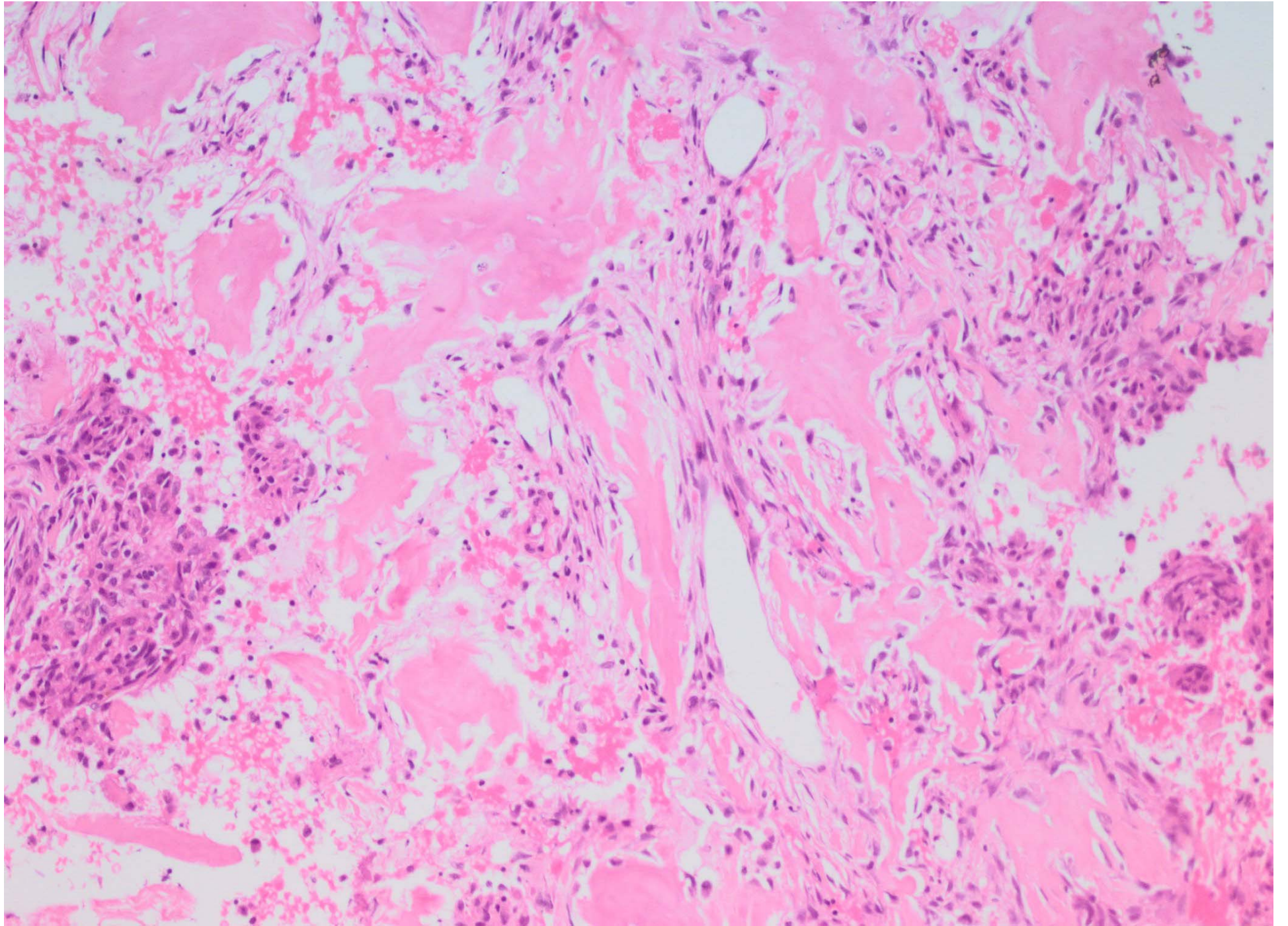


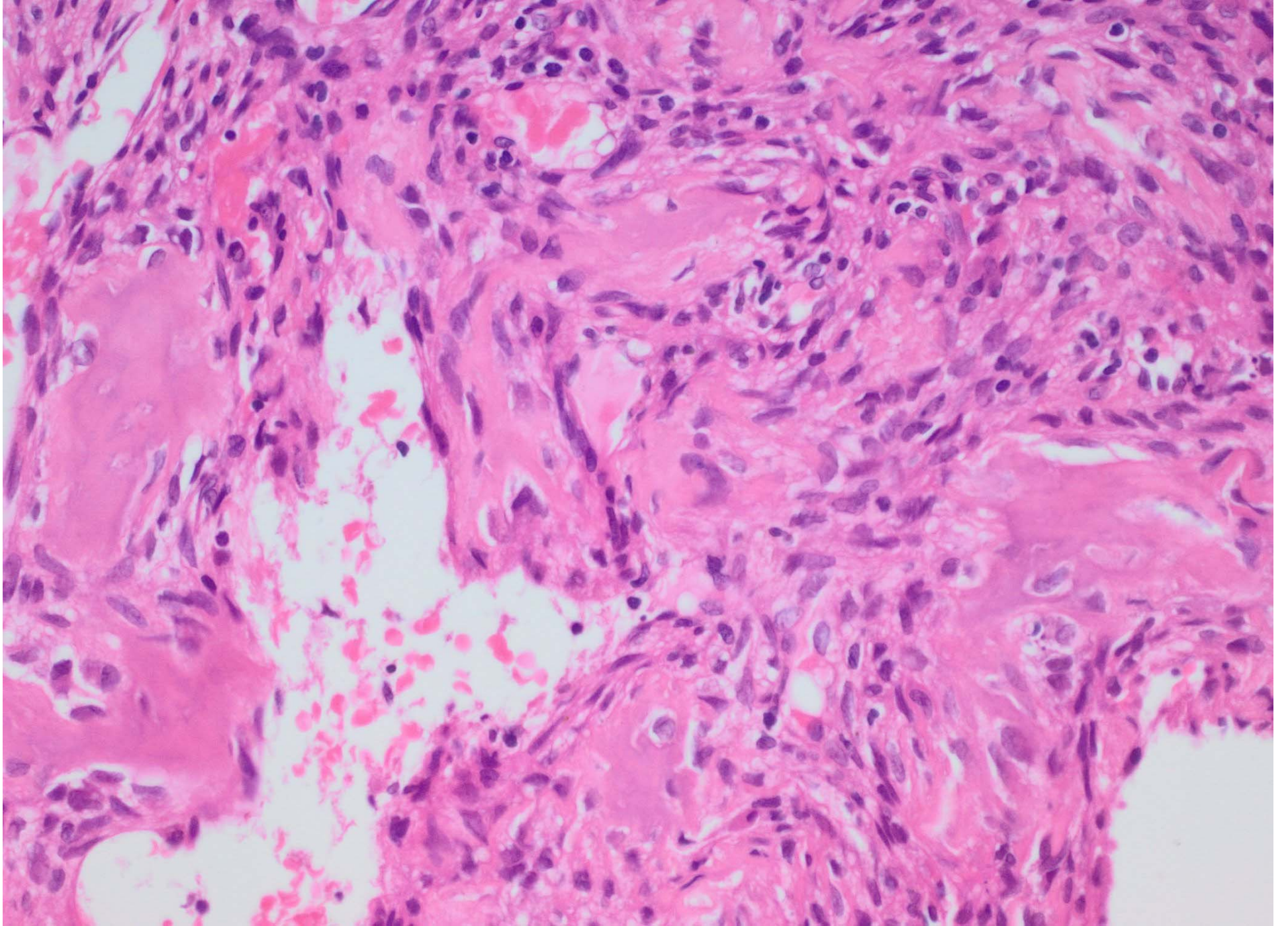


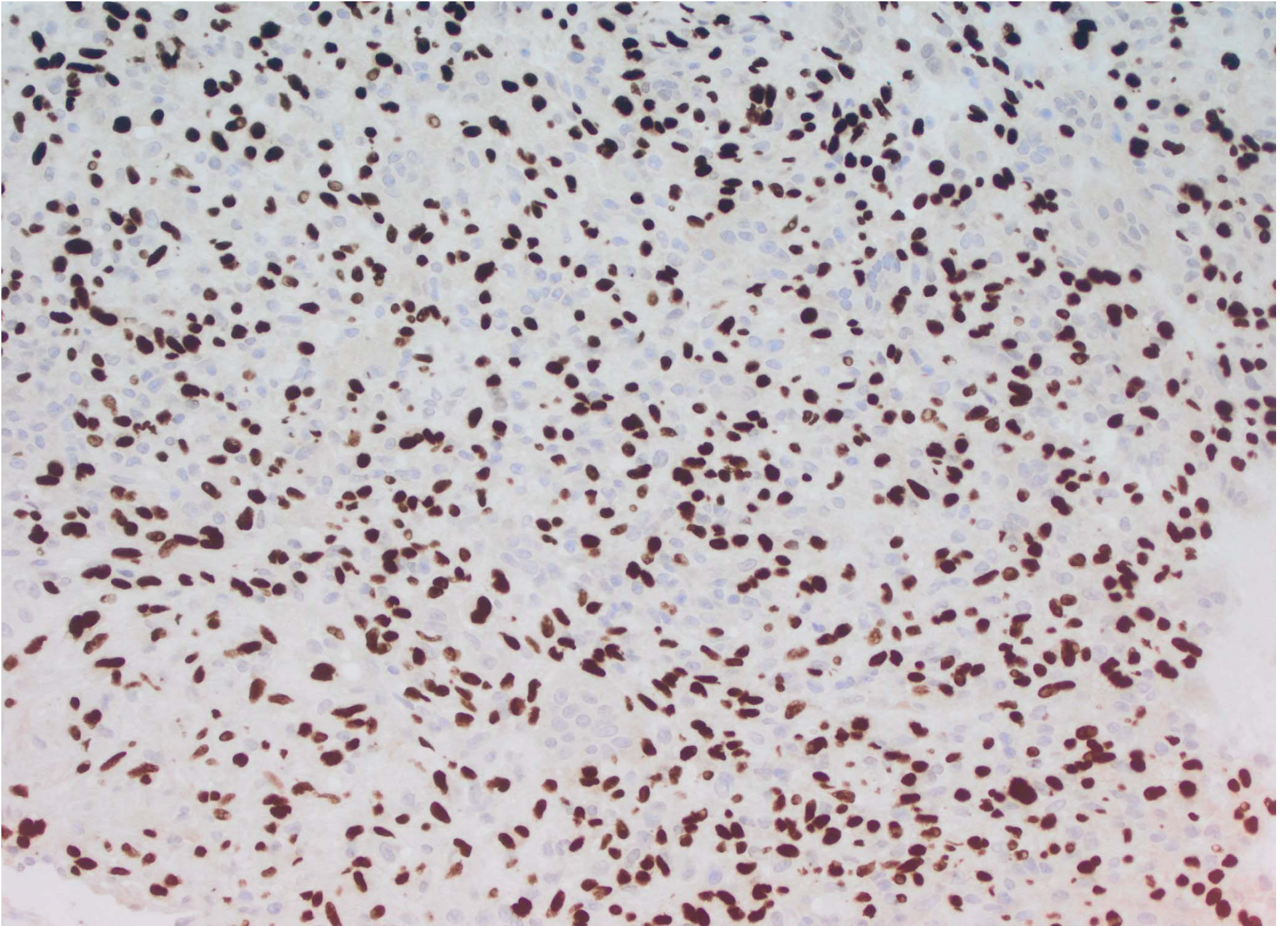












G34W

Clinical Notes *14 year-old Female*

Jan 2017. Presenting with spontaneous fracture of left wrist.

Imaging shown a 35x25mm, well-defined expansile, intramedullary lytic lesion on the left distal radius.

Open biopsy reported as Giant Cell Tumour of Bone.

Mar 2017. Distal radius replacement. Diagnosis confirmed.

Clinical Notes *14 year-old Female*

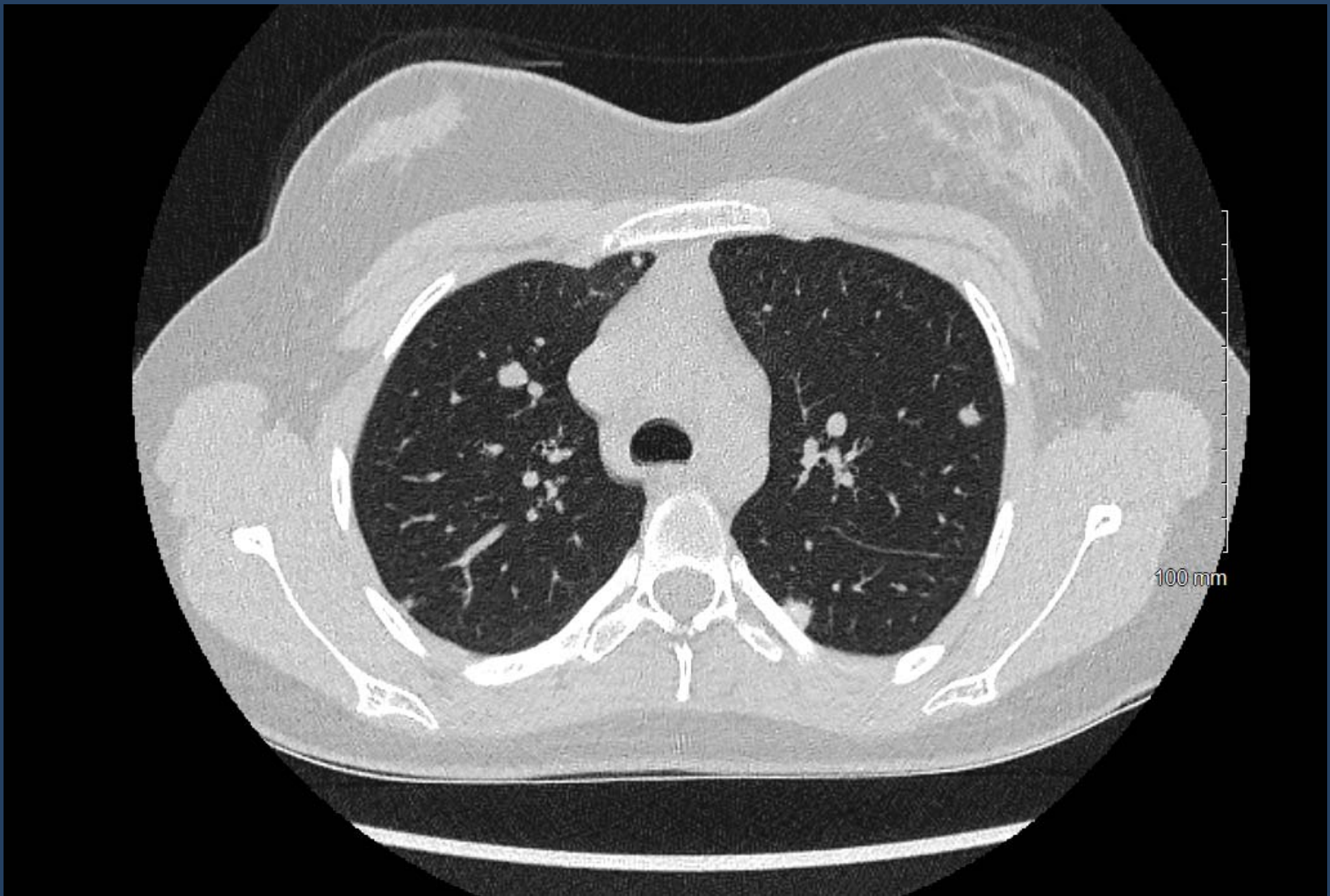
*Jan 2017. Presenting with spontaneous fracture of left wrist.
Imaging shown a 35x25mm, well-defined expansile,
intramedullary lytic lesion on the left distal radius.
Open biopsy reported as Giant Cell Tumour of Bone.*

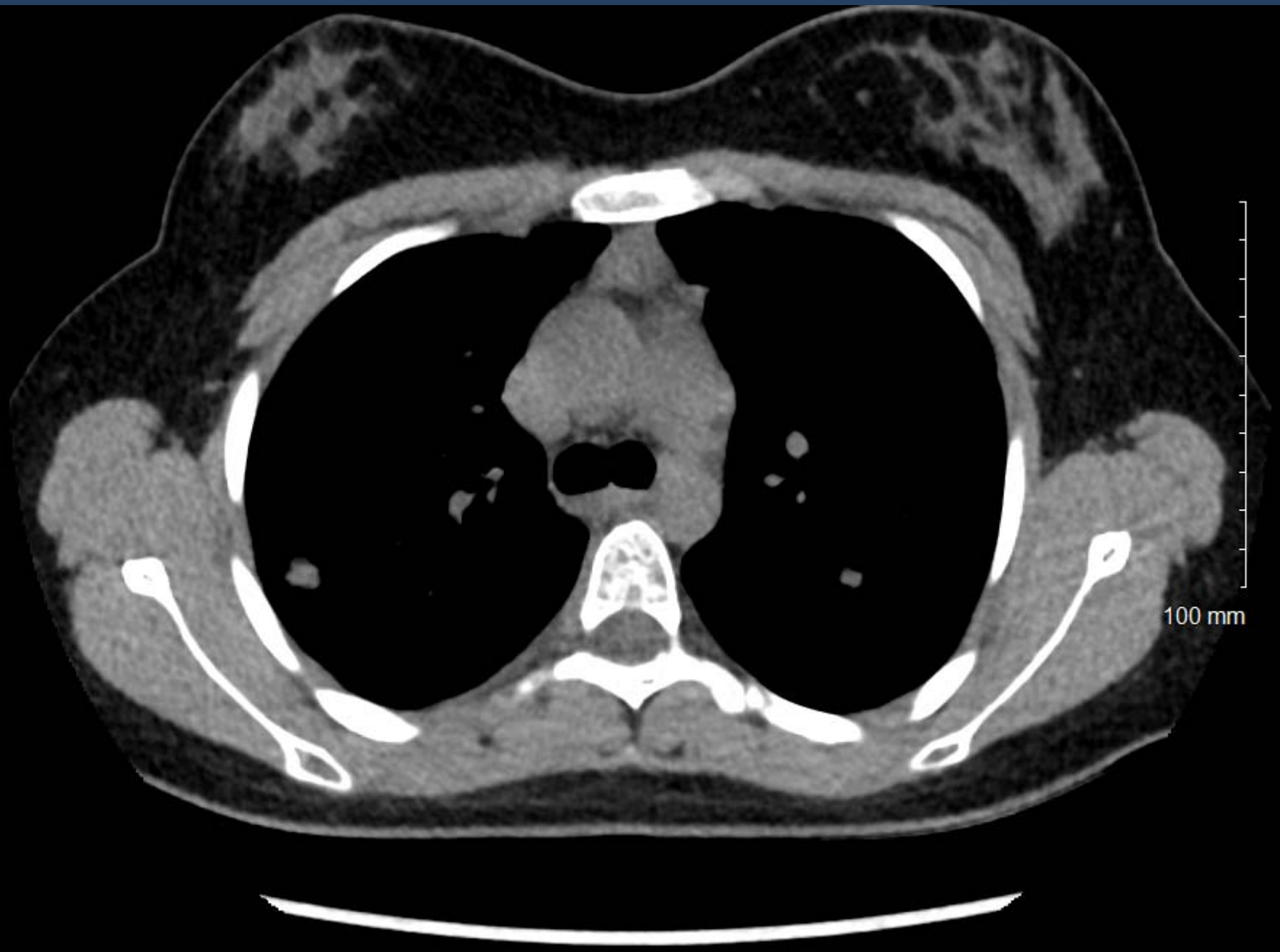
Mar 2017. Distal radius replacement. Diagnosis confirmed.

*July 2017. Severe chest pain. Chest CT shown multiple
bilateral pulmonary nodules, the largest 21mm.
Lung biopsy reported as giant cell-rich Osteosarcoma.*

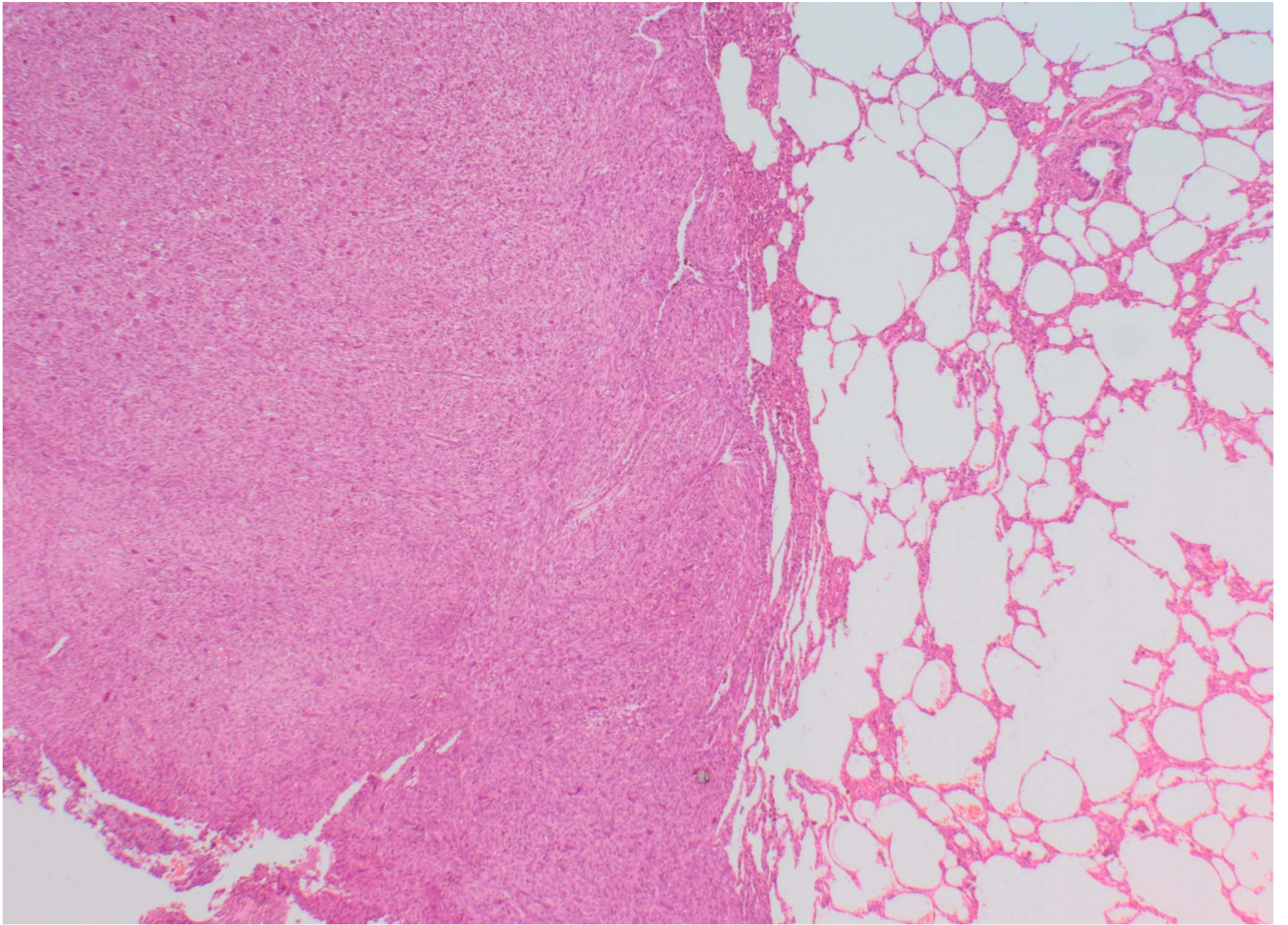
*Aug 2017. MAP Chemotherapy started. Two cycles completed
with no clinical response.*

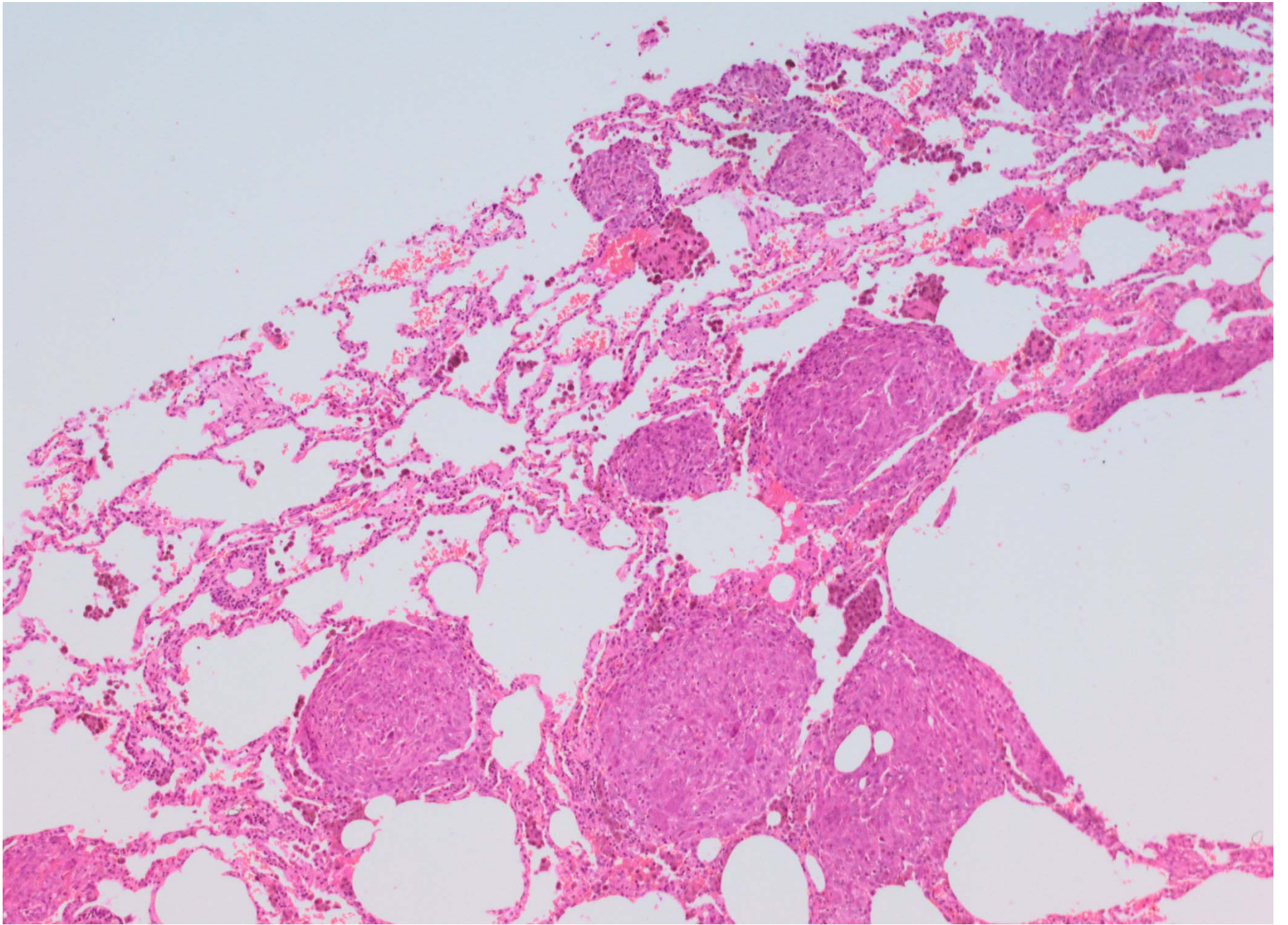
Nov 2017. Referred to The London Sarcoma Service.

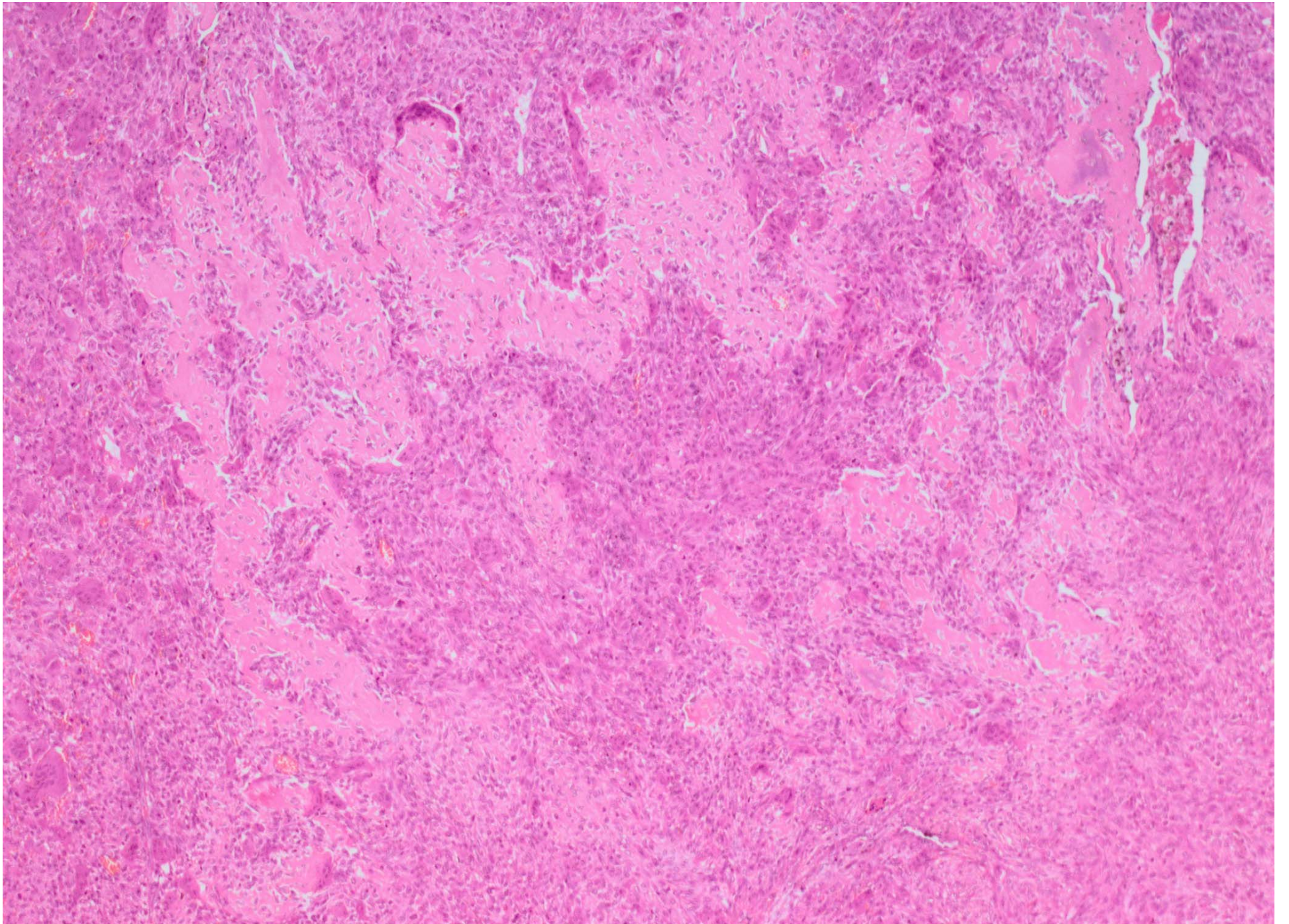


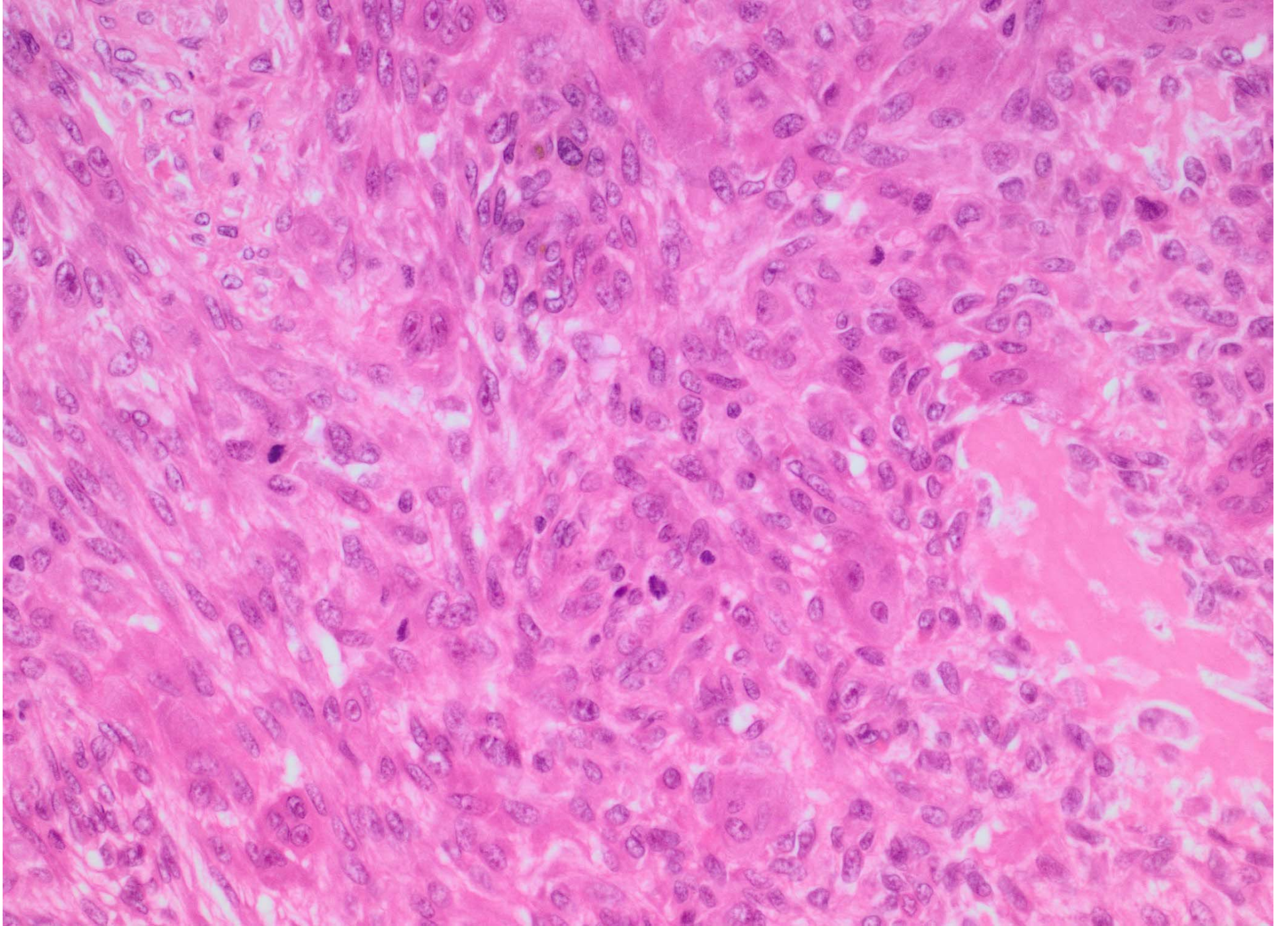


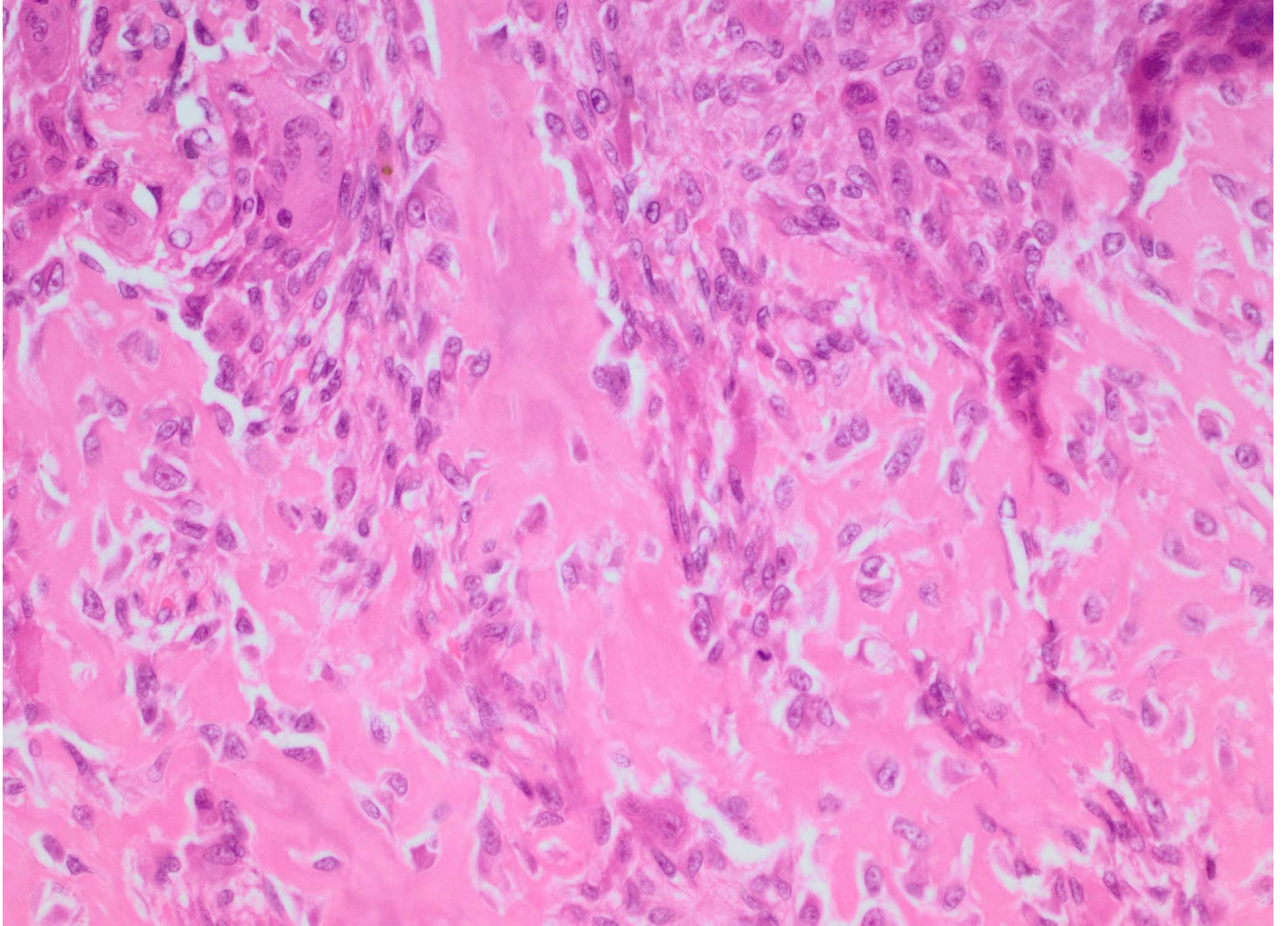
100 mm

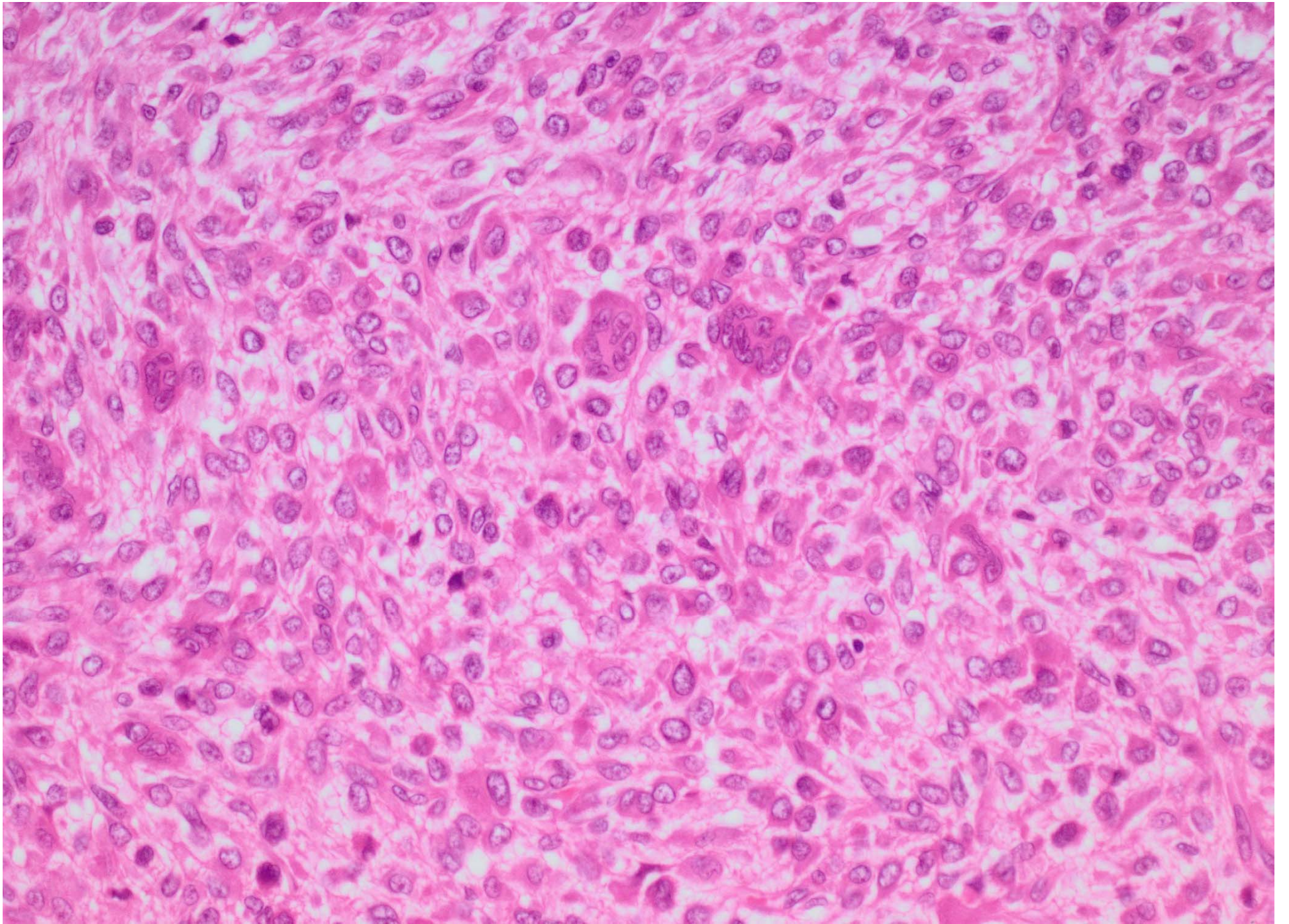


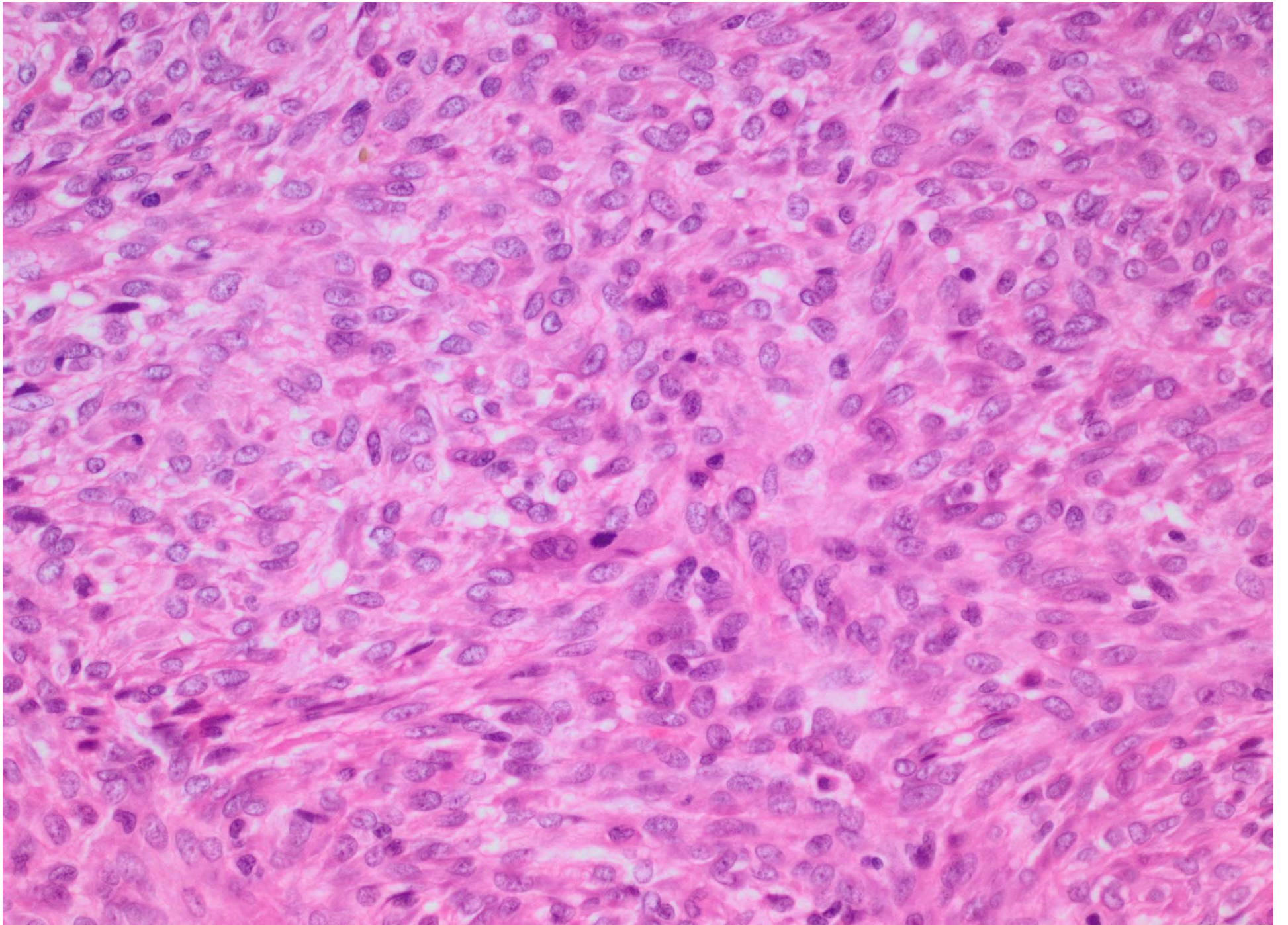


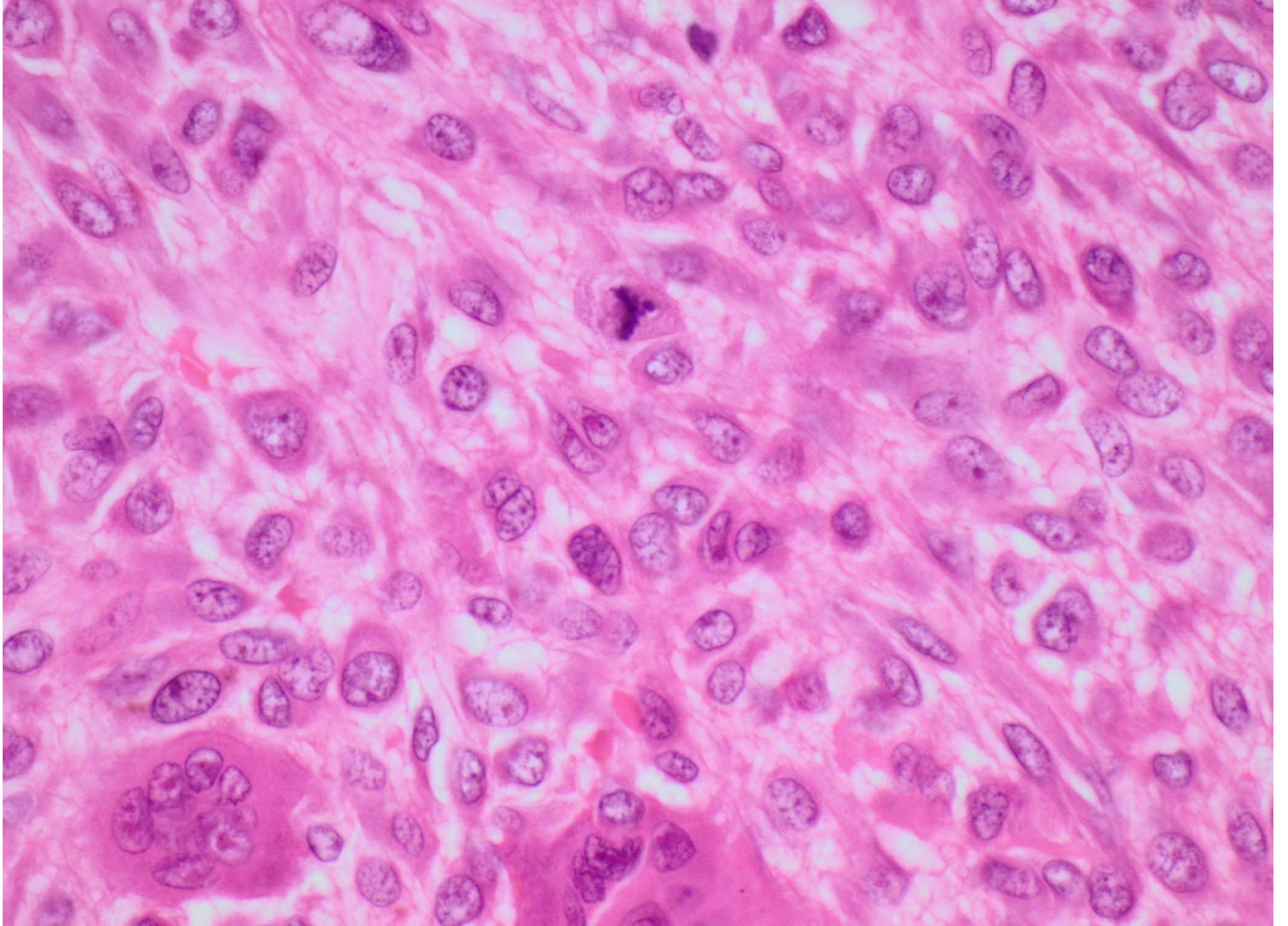


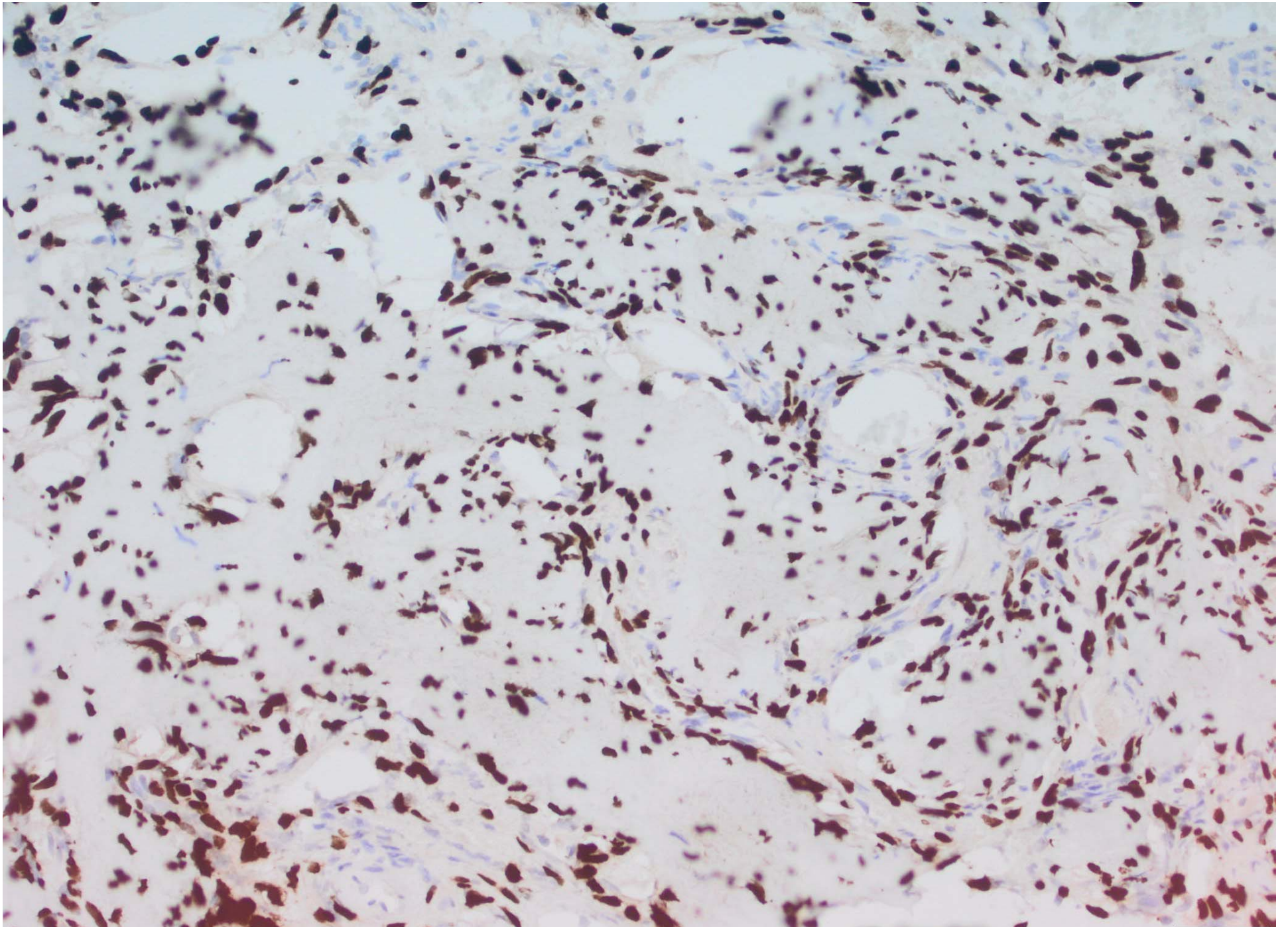








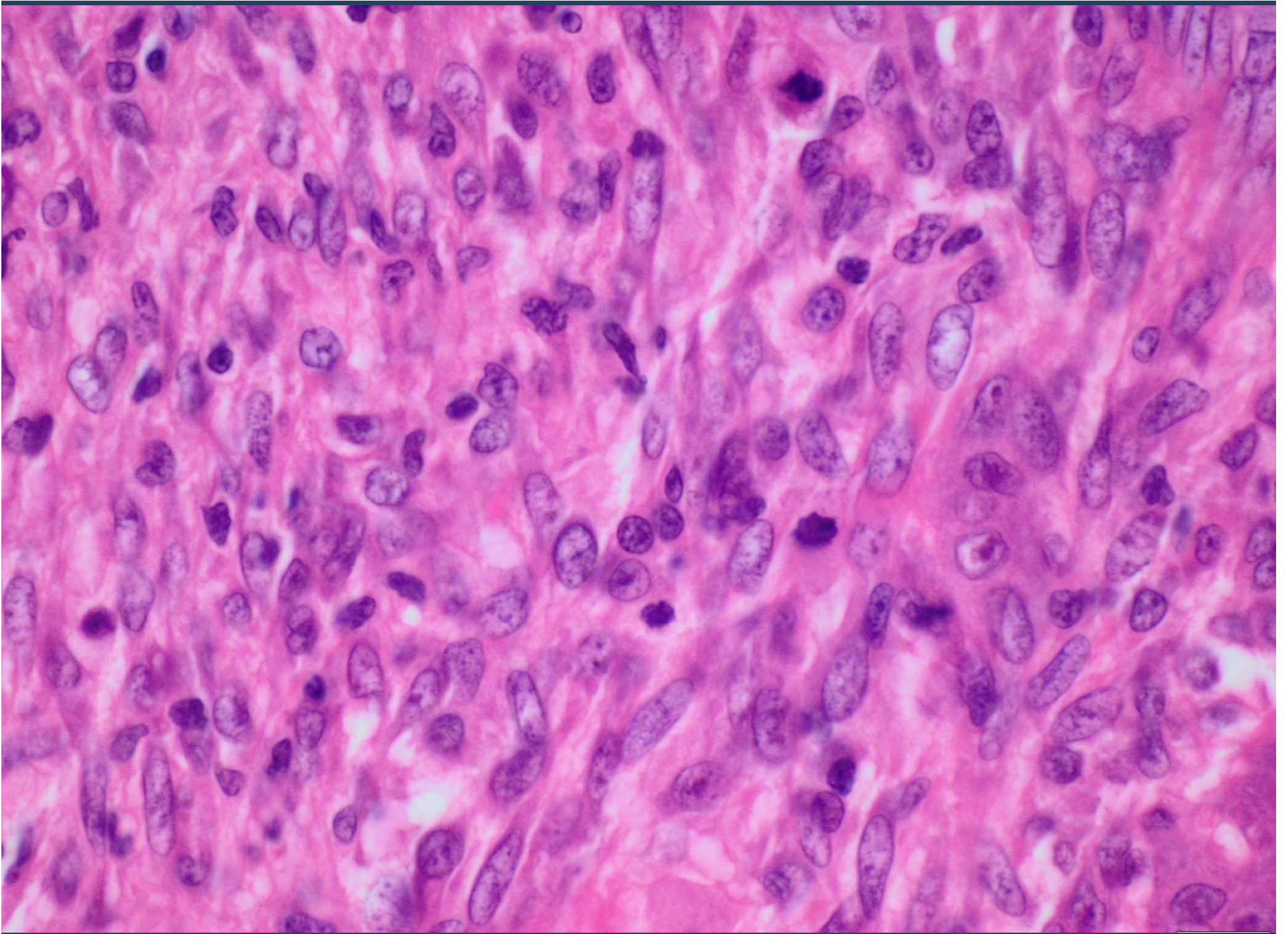




G34W

Reviewed by 6 senior orthopaedic pathologists in the UK / EU and US

- **Conventional metastatic Giant Cell Tumour of Bone**
- **Atypical metastatic Giant Cell Tumour of Bone**
- **Malignant Metastatic Giant Cell Tumour of Bone**
- **Giant Cell-Rich Metastatic Osteosarcoma**

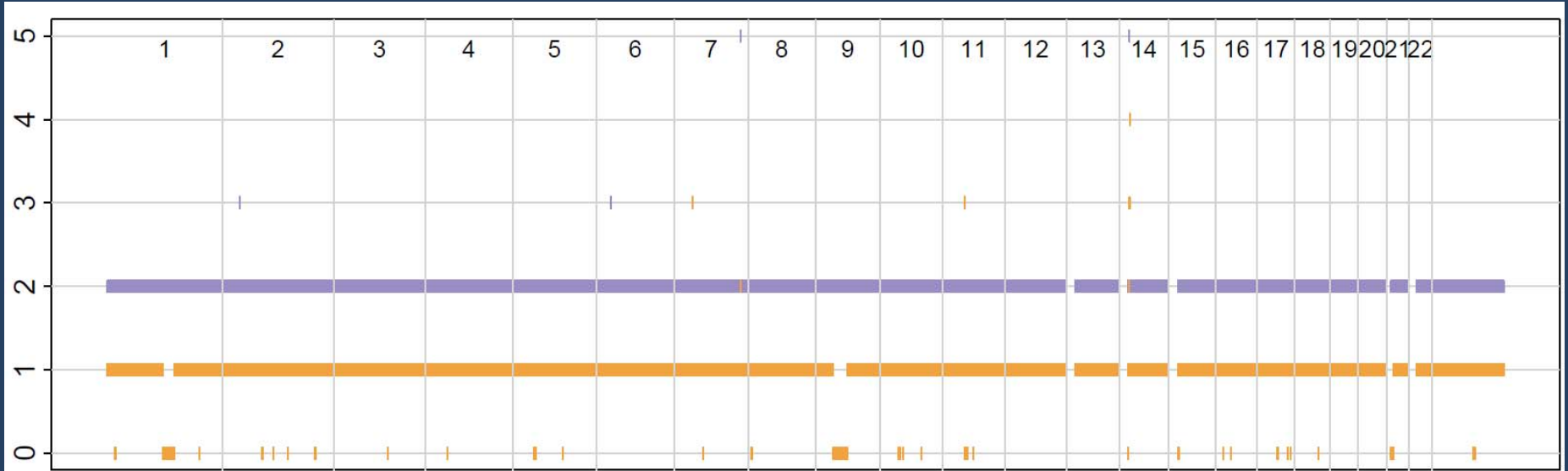


IL FAUT CONFRONTER
LES IDÉES VAGUES AVEC
DES IMAGES CLAIRES

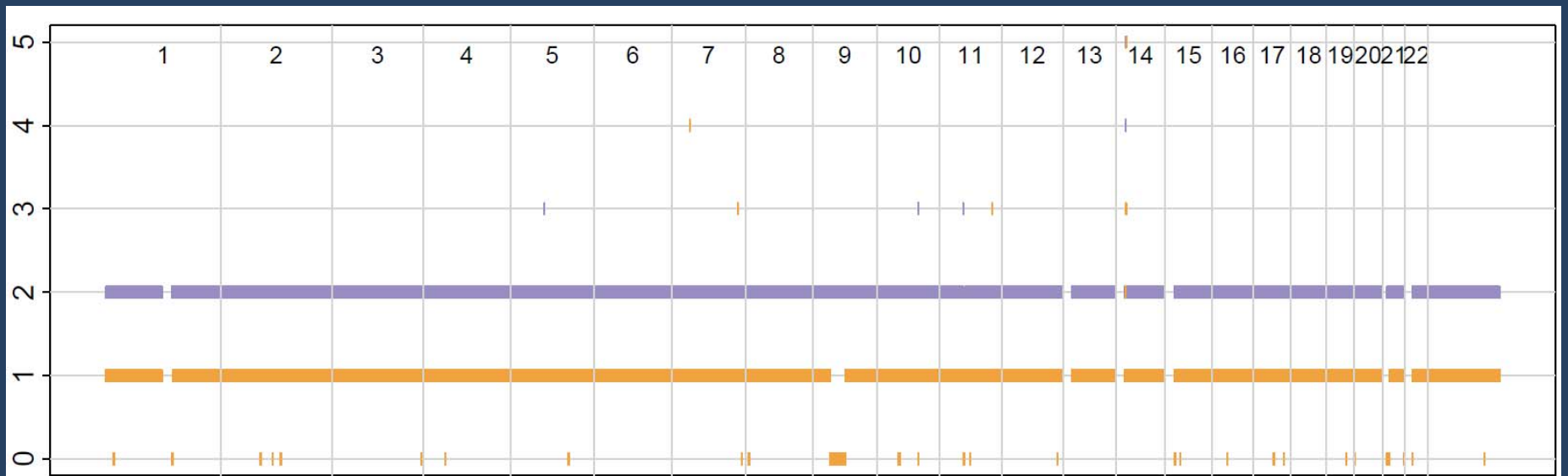


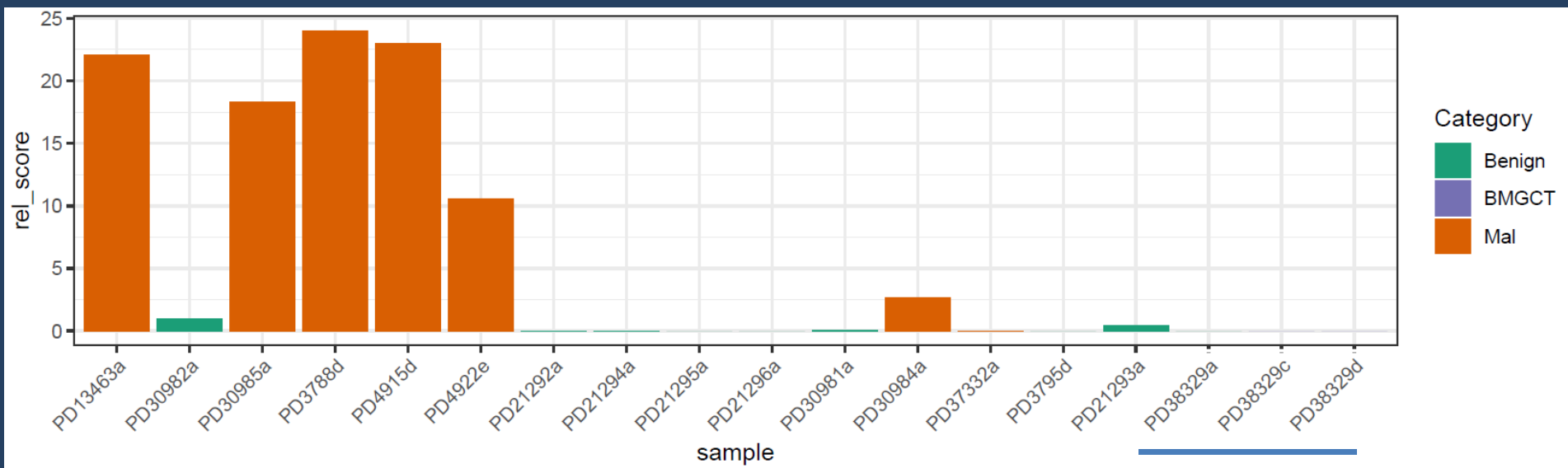
Jean Luc Godard

Copy Number Profile – Primary Tumour



Copy Number Profile – Metastatic Tumour





The following investigations were performed on cohorts of G34W-positive, histologically 'conventional' (n = 38) and 'malignant' (n = 13) GCTs:

	Malignant GCT	Conventional GCT
Whole genome sequencing (WGS)	10/13 cases	4/38 cases
DNA methylation profiling (Illumina 450K/EPIC)	11/13 cases	22/38 cases
SNP array (Illumina Omni2.5 array)	5/13 cases	16/38 cases

Data were also compared with those generated from Osteosarcoma without H3.3 mutations (n =35).

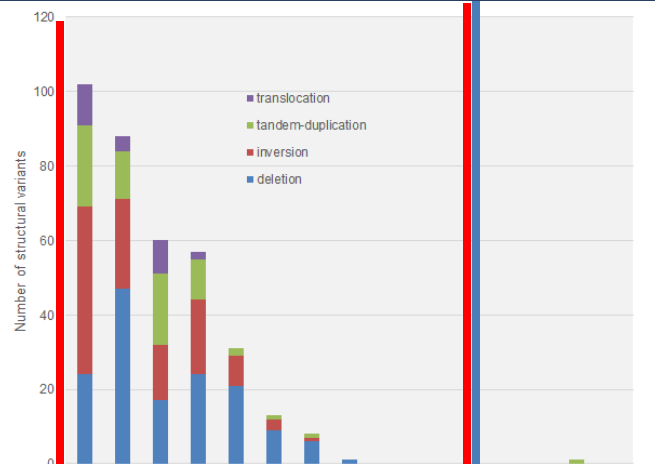
The data were analysed blinded to the histological subtypes and the clinical outcome

Malignant GCT genomes differ from both conventional GCT and osteosarcoma

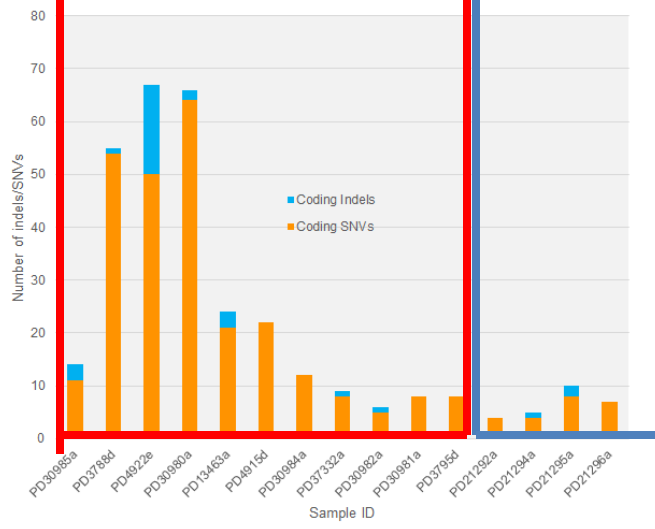
Malignant GCT
no. 10

Conventional GCT
no. 4

A




B

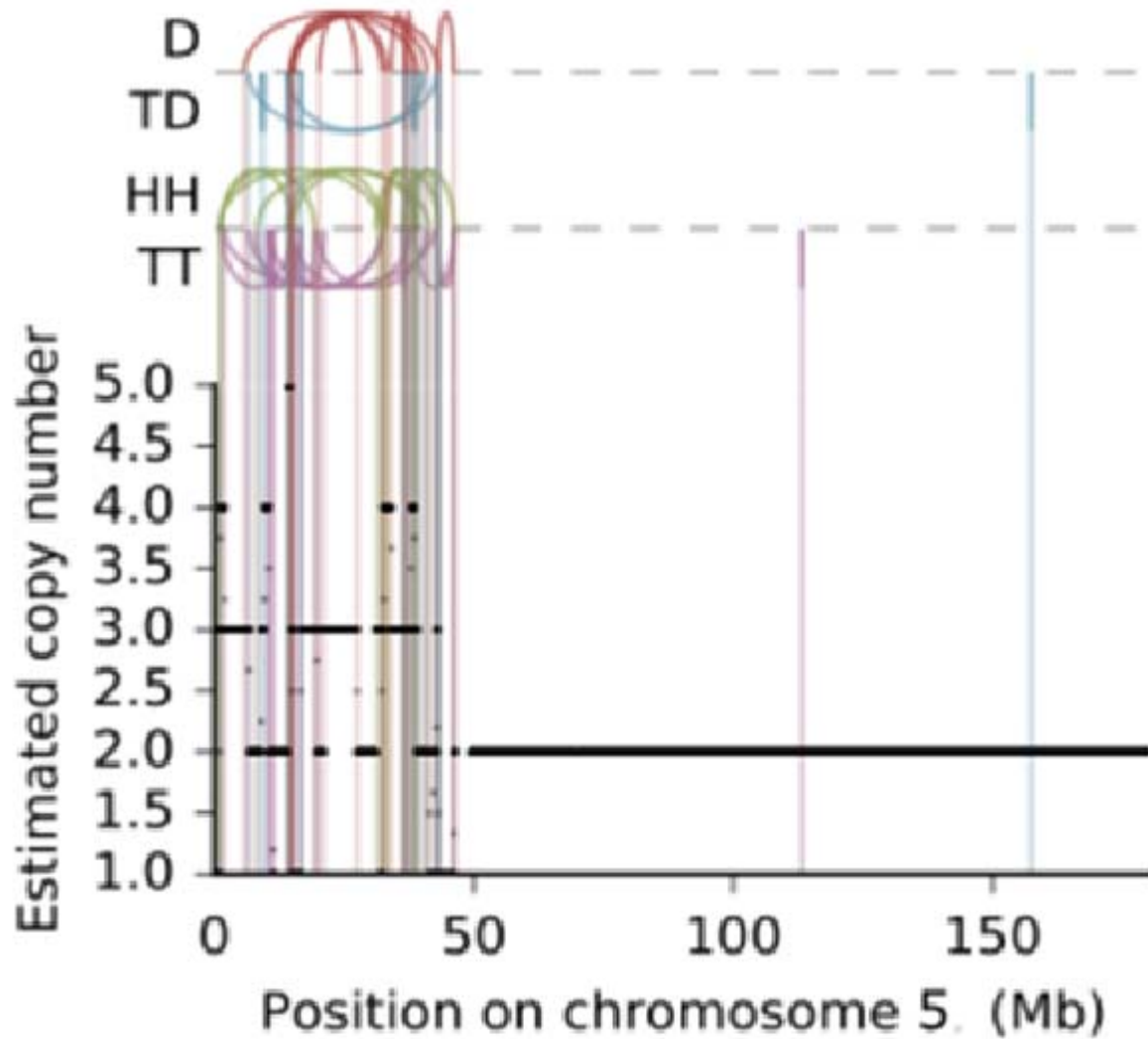


A. Bar chart showing the number and type of structural variants (SVs) by sample. SV burden varied widely between individual cases of malignant GCT (median 10.5; range 0-102), but were virtually absent from conventional GCT.

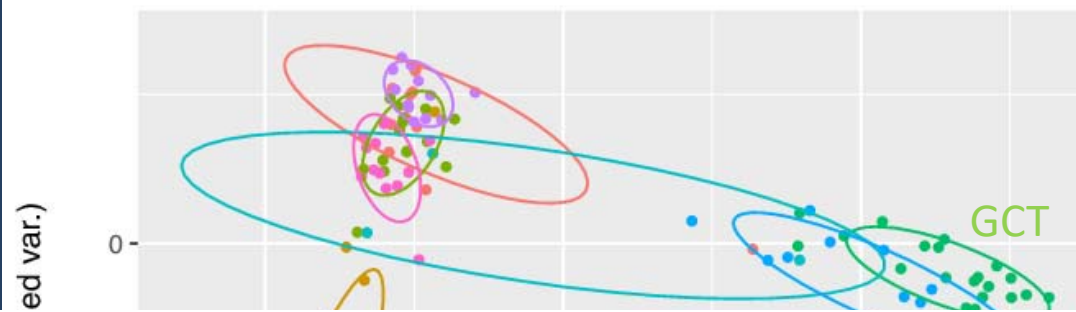
B. Bar chart showing the number of coding substitutions and indels by sample. The median coding mutation burden for malignant GCT was 12 (range 5-64). Virtually no established cancer driver mutations were identified. In particular contrast to conventional osteosarcoma, *TP53* and *RB1* mutations were not identified in any cases



■ Point mutations
■ Structural variants



Representative example of chromothripsis, detected in 2/10 malignant GCT genomes. Kataegis was detected in 4/10 malignant GCT (data not shown). No conventional GCT samples contained evidence of chromothripsis or kataegis.

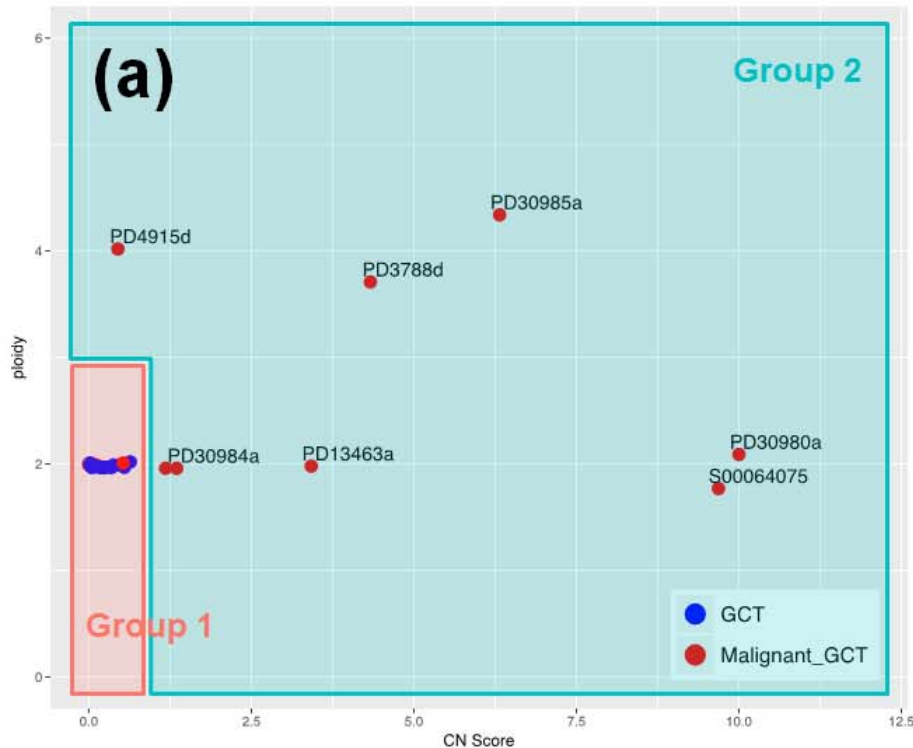


- Aneurysmal_Bone_Cyst
- Chondroblastoma
- Chondromyxoid_Fibroma
- Giant_Cell_Tumour_of_Bone
- Giant_Cell_Tumour_of_Bone_G34_WT
- Malignant bone tumour (G34 mut)
- Nonossifying_Fibroma
- Osteoblastoma

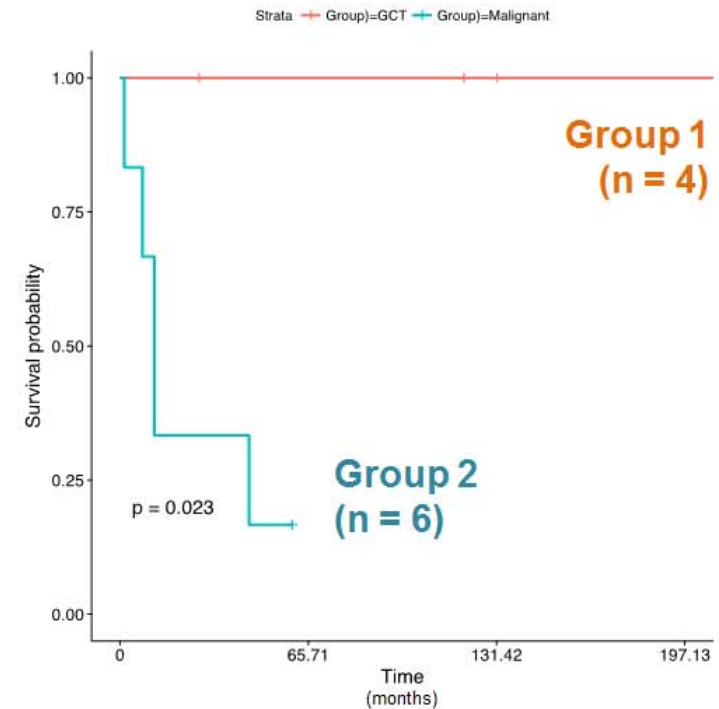
Malignant and conventional GCT both show global DNA hypermethylation but cannot be reliably separated by DNA methylation profiling

Scatter plot showing principal component analysis (PCA) of genome-wide DNA methylation profiles for conventional and malignant GCT (n = 34), and a range of benign bone tumours without *H3F3A* p.G34 substitutions (n = 87). Malignant and conventional GCT both show global DNA hypermethylation, but could not be reliably separated from one another on the basis of PCA, hierarchical clustering or differentially methylated regions.

Ploidy and copy number score are prognostic markers for H3.3-mutated bone tumours



(b)



(a) Scatter plot of sample ploidy against copy number score for conventional GCT and malignant GCT.

(b) Kaplan-Meier survival curves for the two malignant GCT subgroups (time in months).

	Group 1 Conventional GCT (n = 4)	Group 1 Malignant GCT (n = 4)	Group 2 Malignant GCT (n = 6)
Age	Median 27.5 (22-50)	Median 18.5 (15-29)	Median 42.5 (25-53)
Coding subs/indels	Median 6 (4-10)	Median 8 (6-9)	Median 23 (12-66)
Structural variants	Median 0 (0-1)	Median 0 (0-1)	Median 44 (8-102)
Chromothripsis	0/4	0/4	2/6
Kataegis	0/4	0/4	4/6
Clinical outcome (alive at 5 years)	100%	100%*	20%**

*Summary of clinical and genomic features of the proposed GCT groupings. *Data available for 3/4 cases; **Data available for 5/6 cases*

15.10.2018 | 08:30 - 10:00 | Al Haranah 2 (F2)

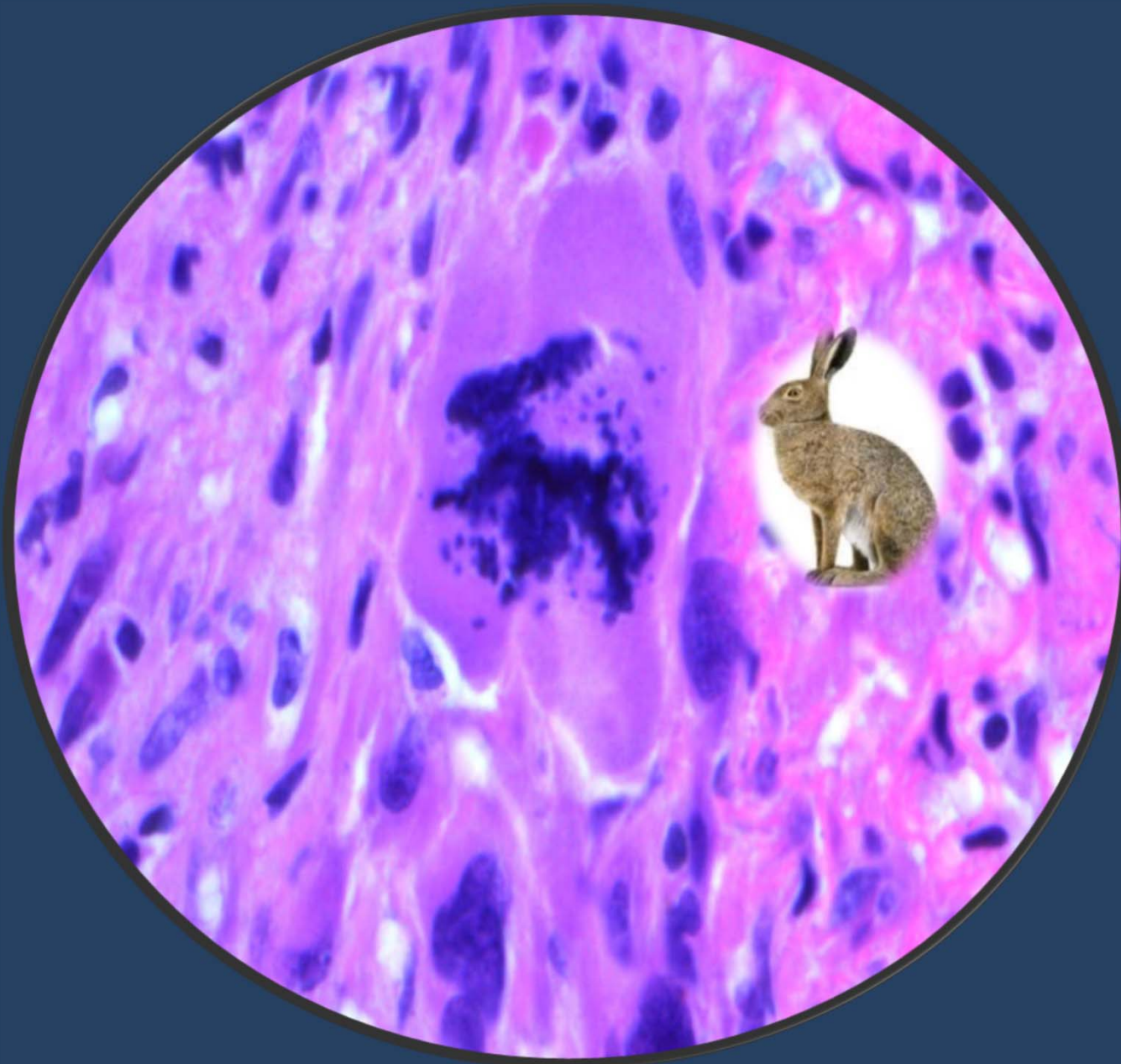


SL-02-I MIMICS OF MALIGNANCY: AN EMPHASIS ON MICROSCOPIC FEATURES AND BEST USE OF LIMITED MOLECULAR TESTS

[View session details and speaker](#) 

An array-based platform may be used as an ancillary diagnostic tool, as:

- It takes less than a week
- It costs £€\$\$ than a FISH



Thank You